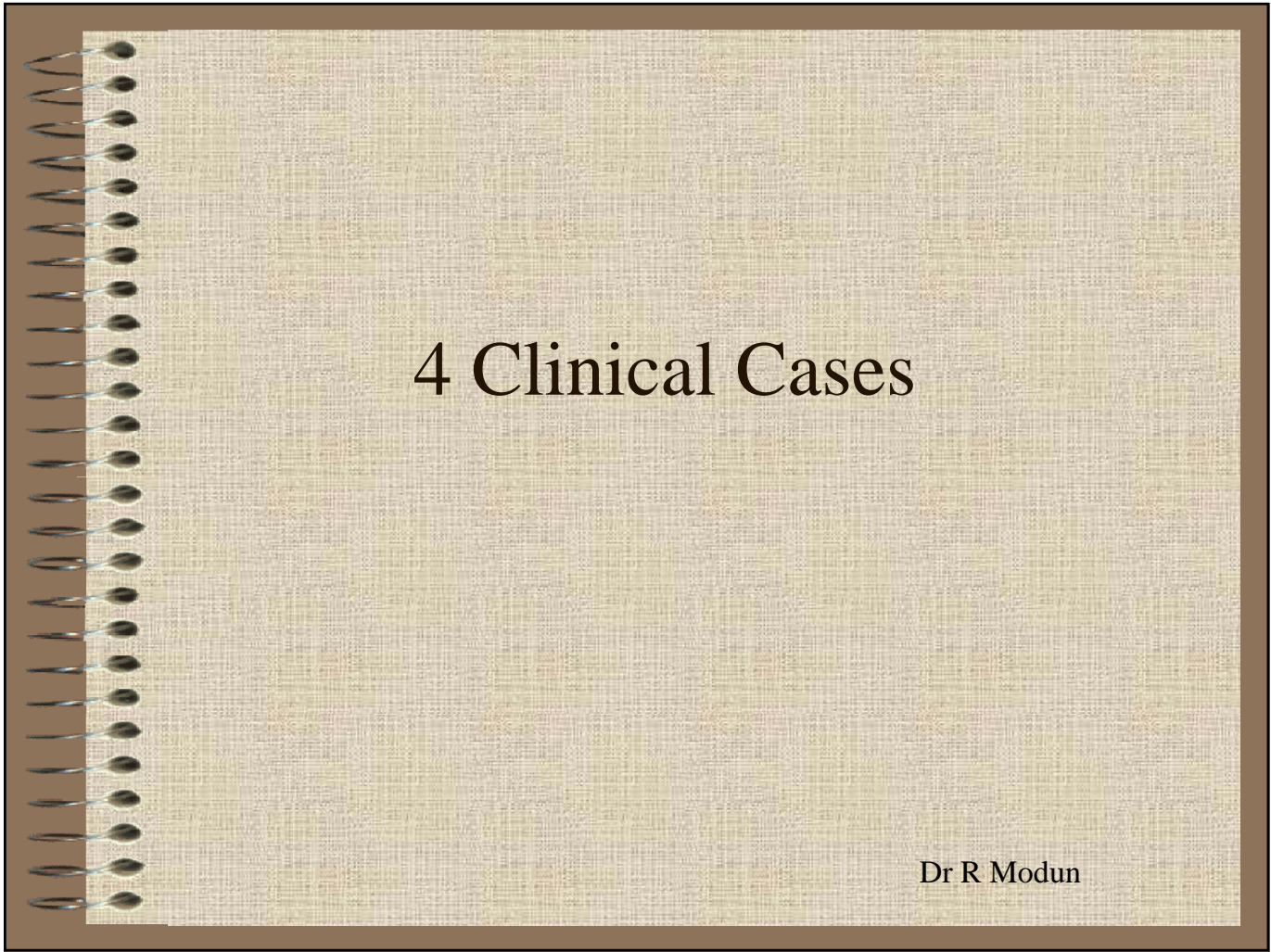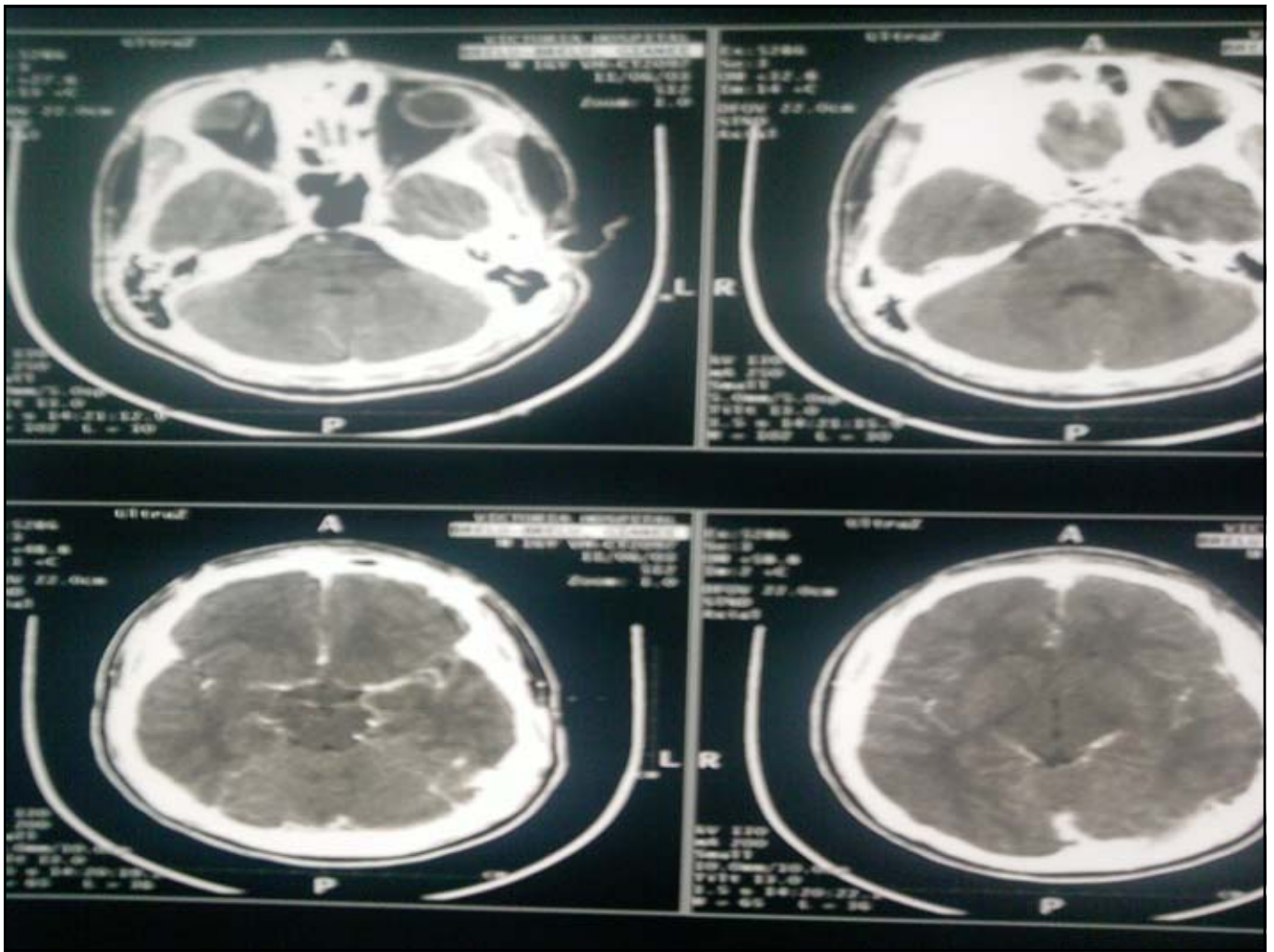
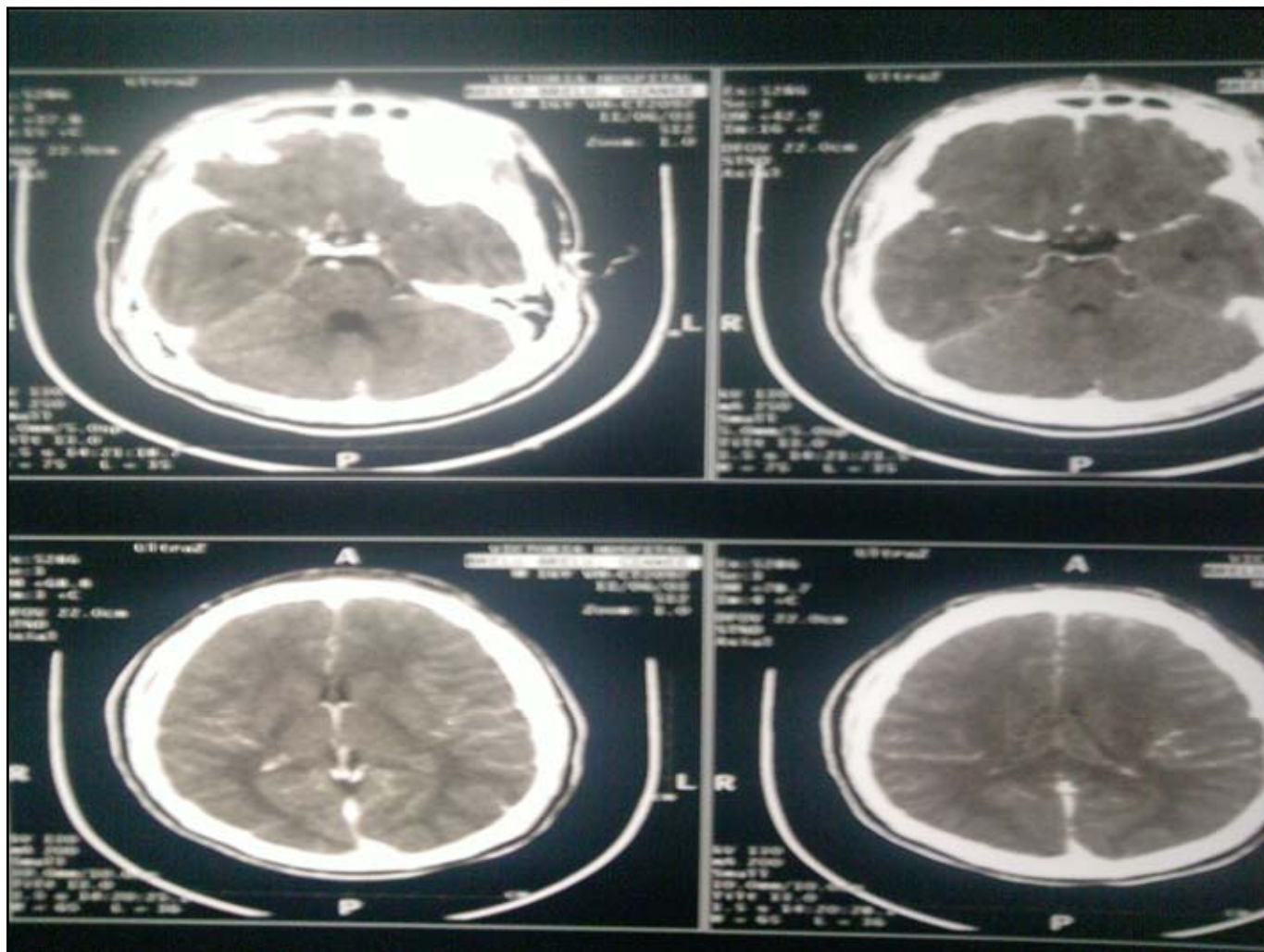


Clinical Case 1

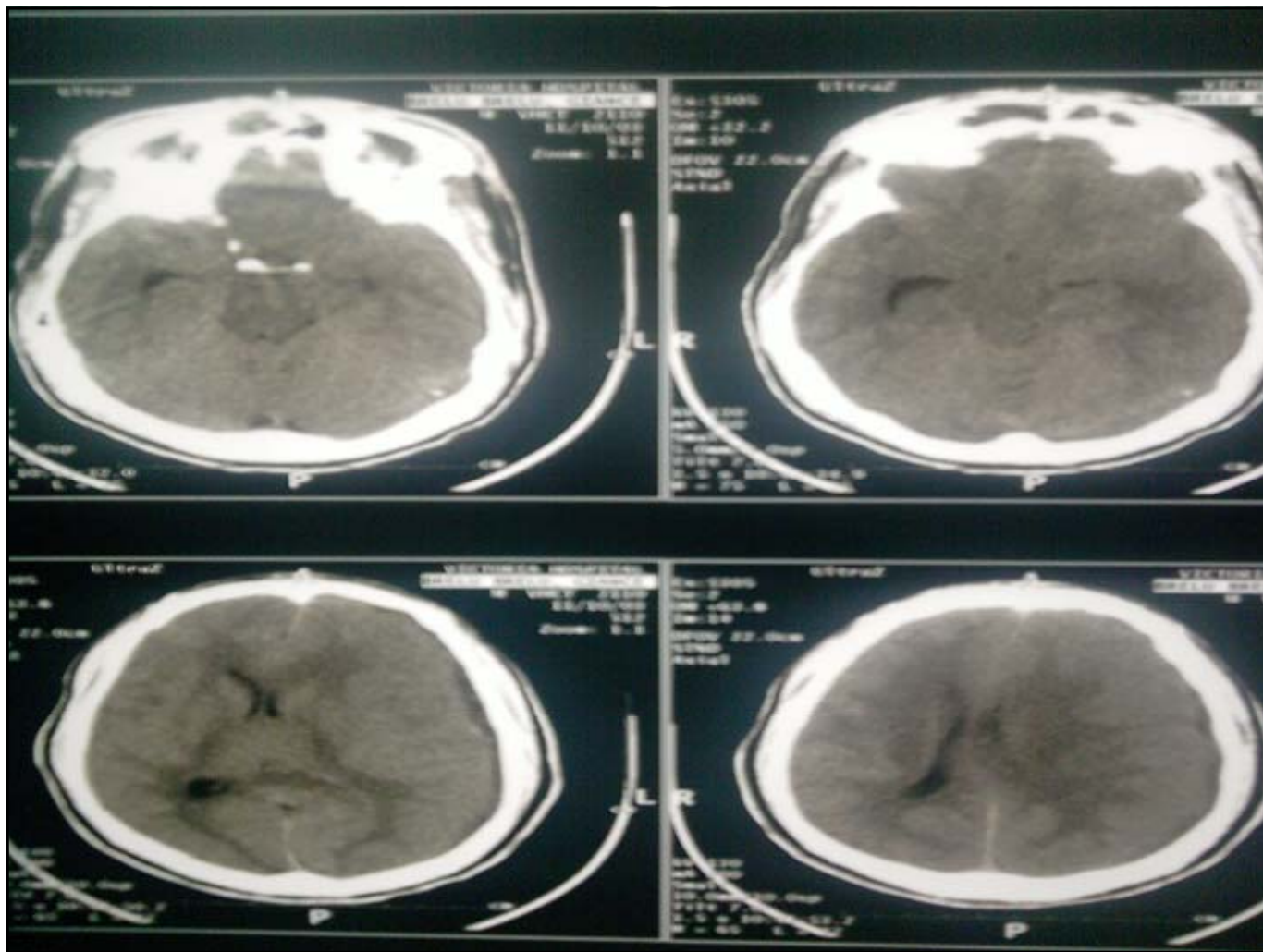
- 16 years old boy
- Came to Hospital complaining of severe headache
- Symptomatic tt with paracetamol and piriton
- Came back 2 days later
- Fever, severe headache
- Admitted. CT Brain...

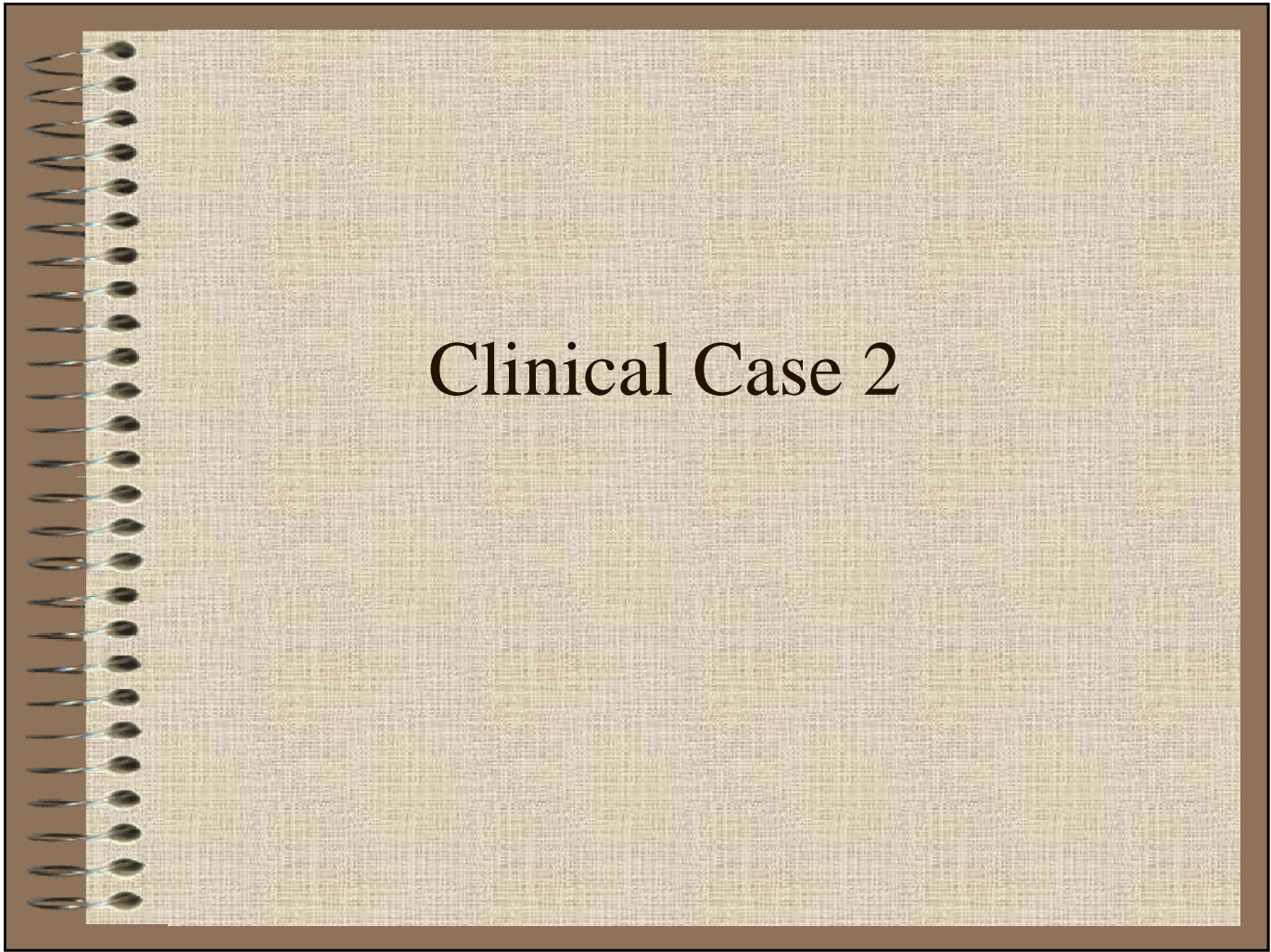




Clinical Case 1...

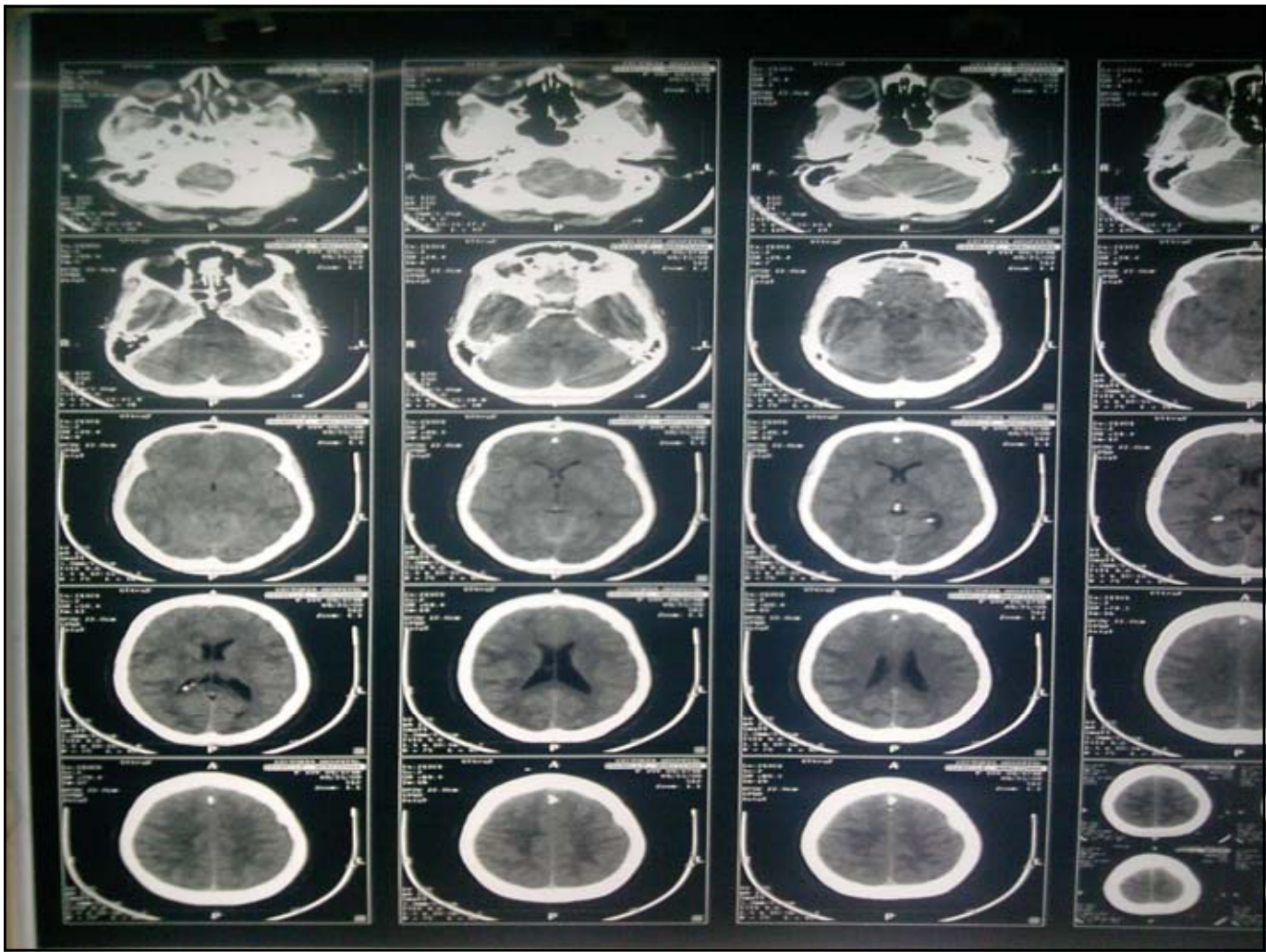
- While in ward...
- Epileptic fits
- Lumbar Puncture. NAD.
- Shifted to ICU
- ...by which time he developed hemiparesis

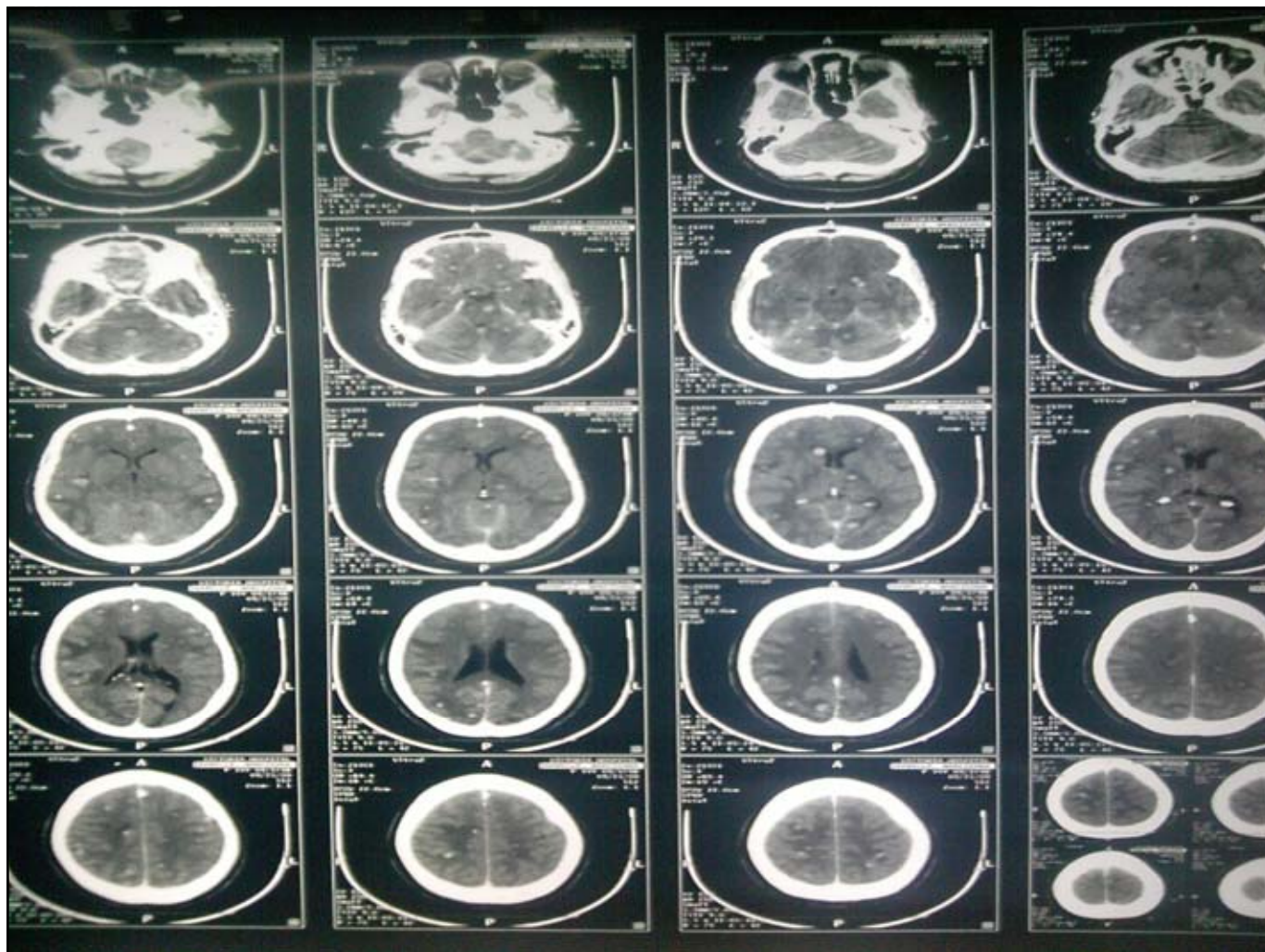


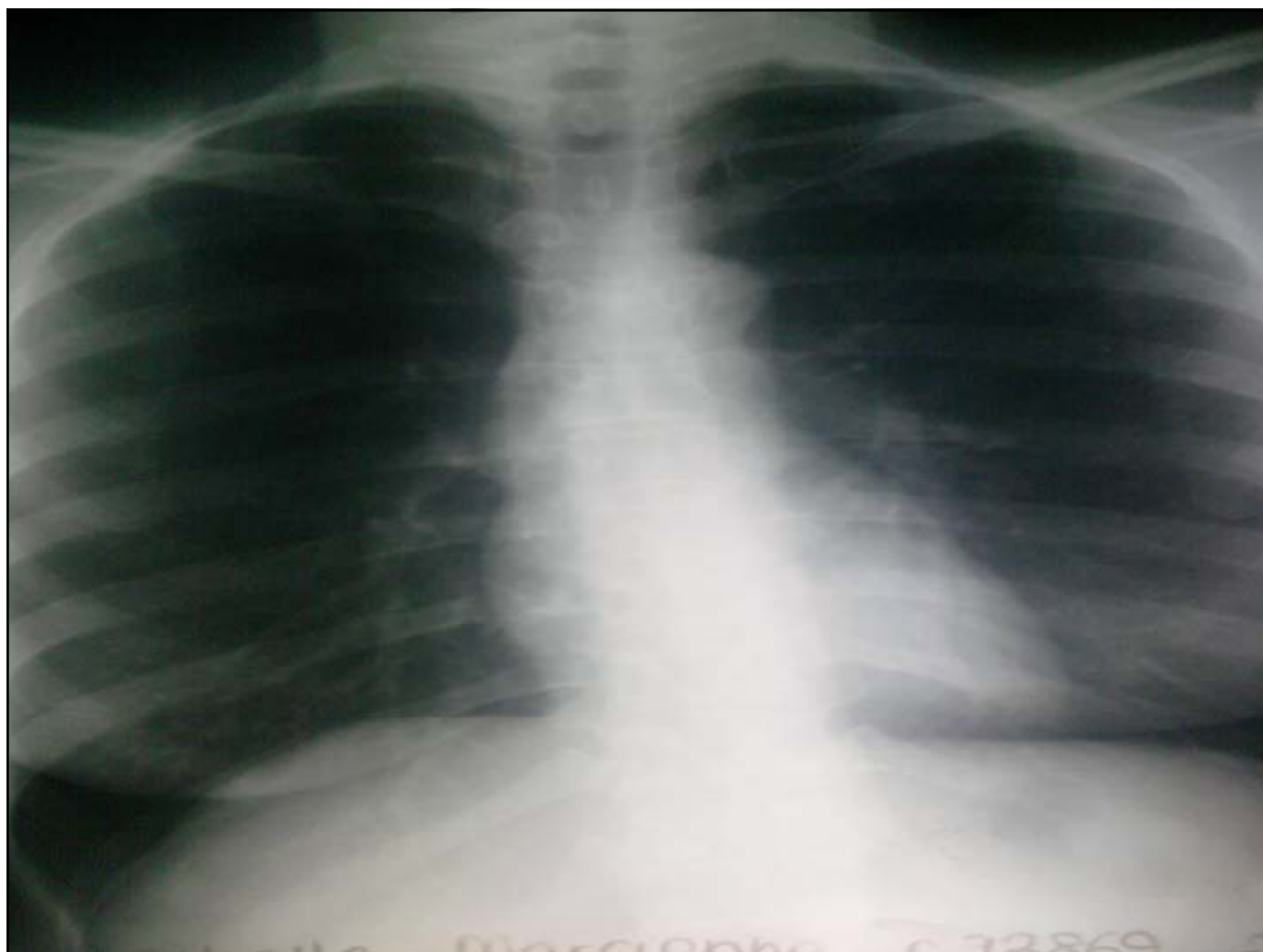

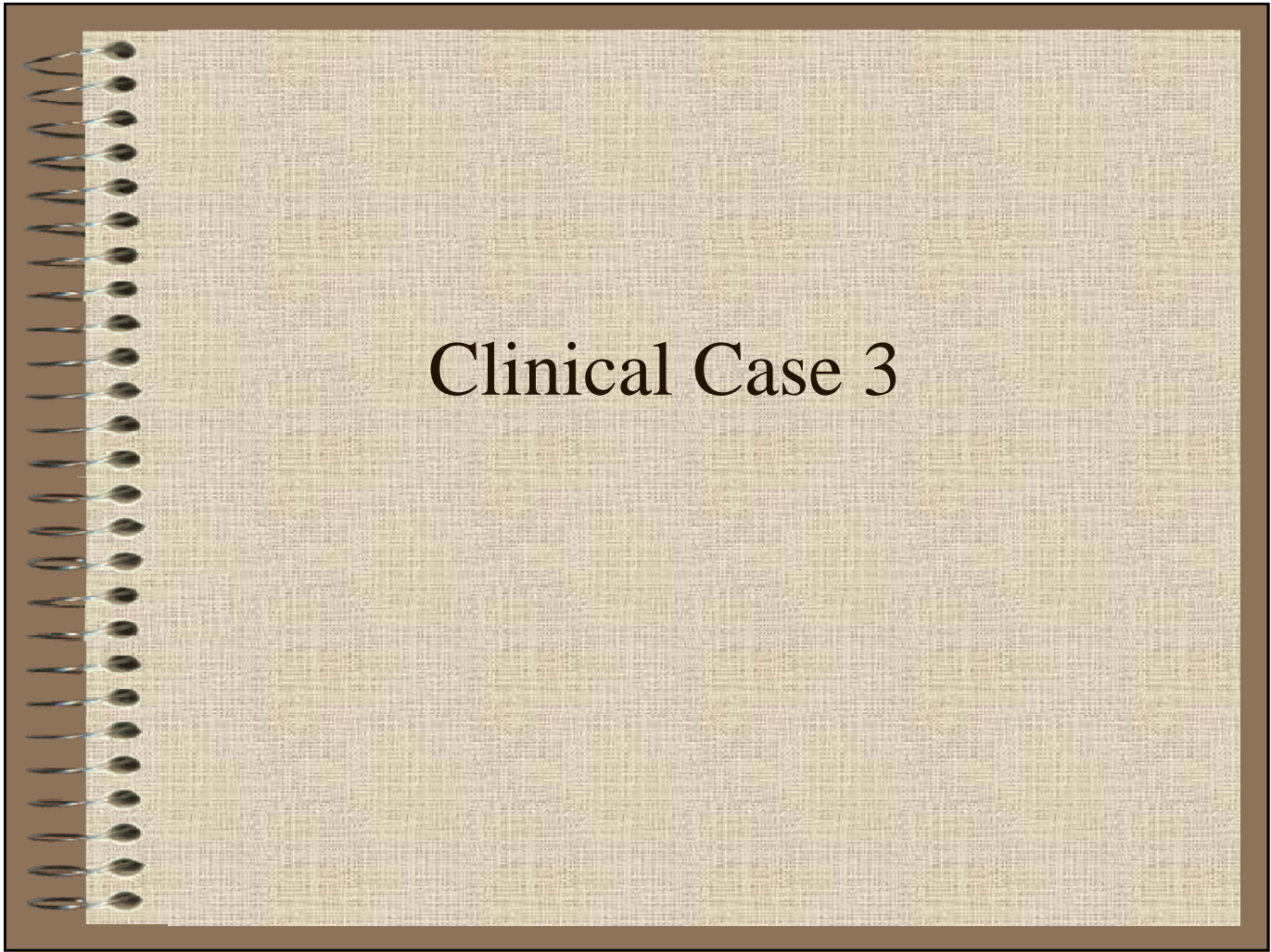
Clinical Case 2

- Mrs M
- Swelling left parotid region
- Attended ENT
- Antibiotics, allowed home
- Not relieved, swelling increased in size, fluctuant, tender, purulent discharge
- Pus sent for m+c+s







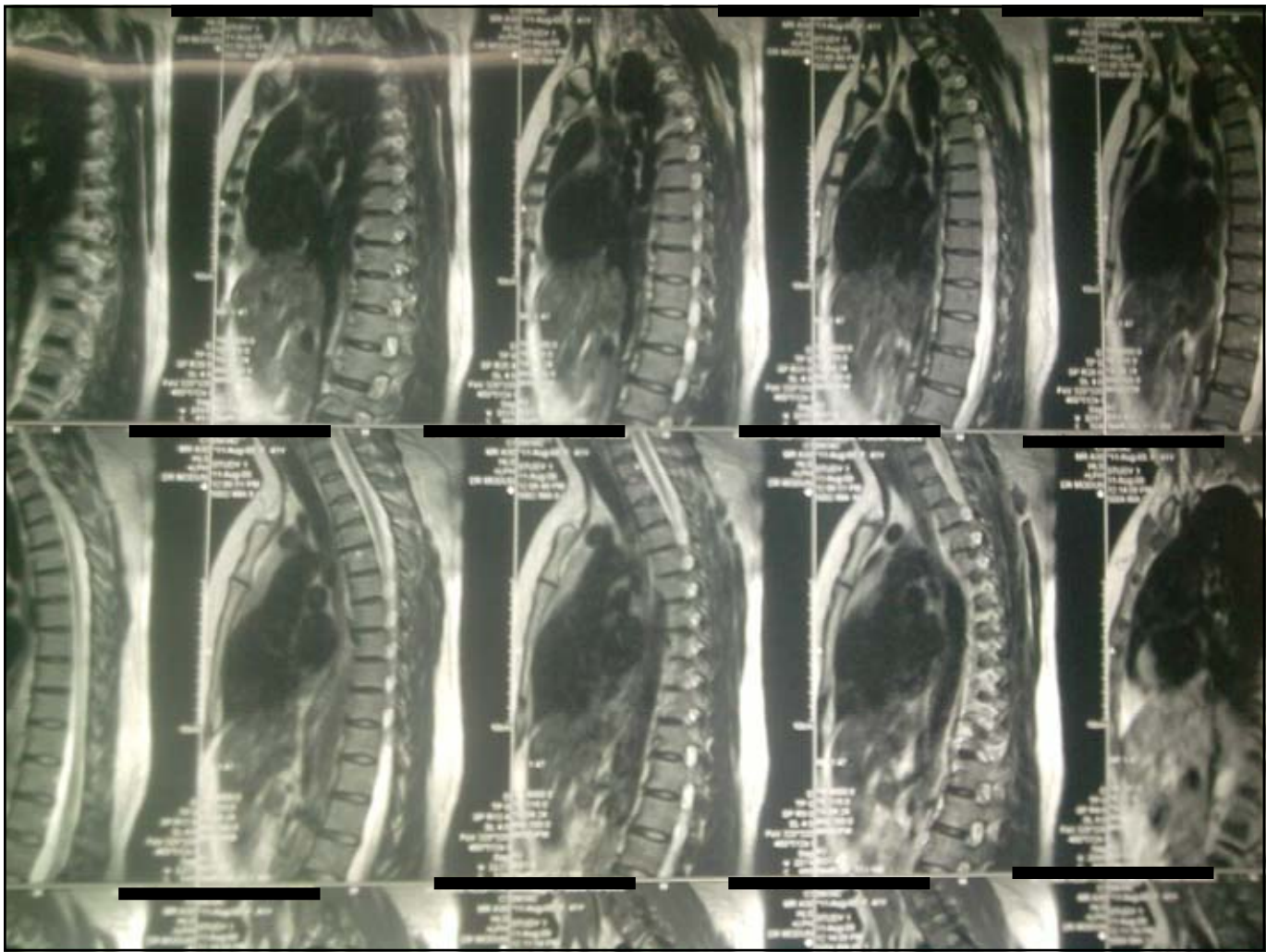


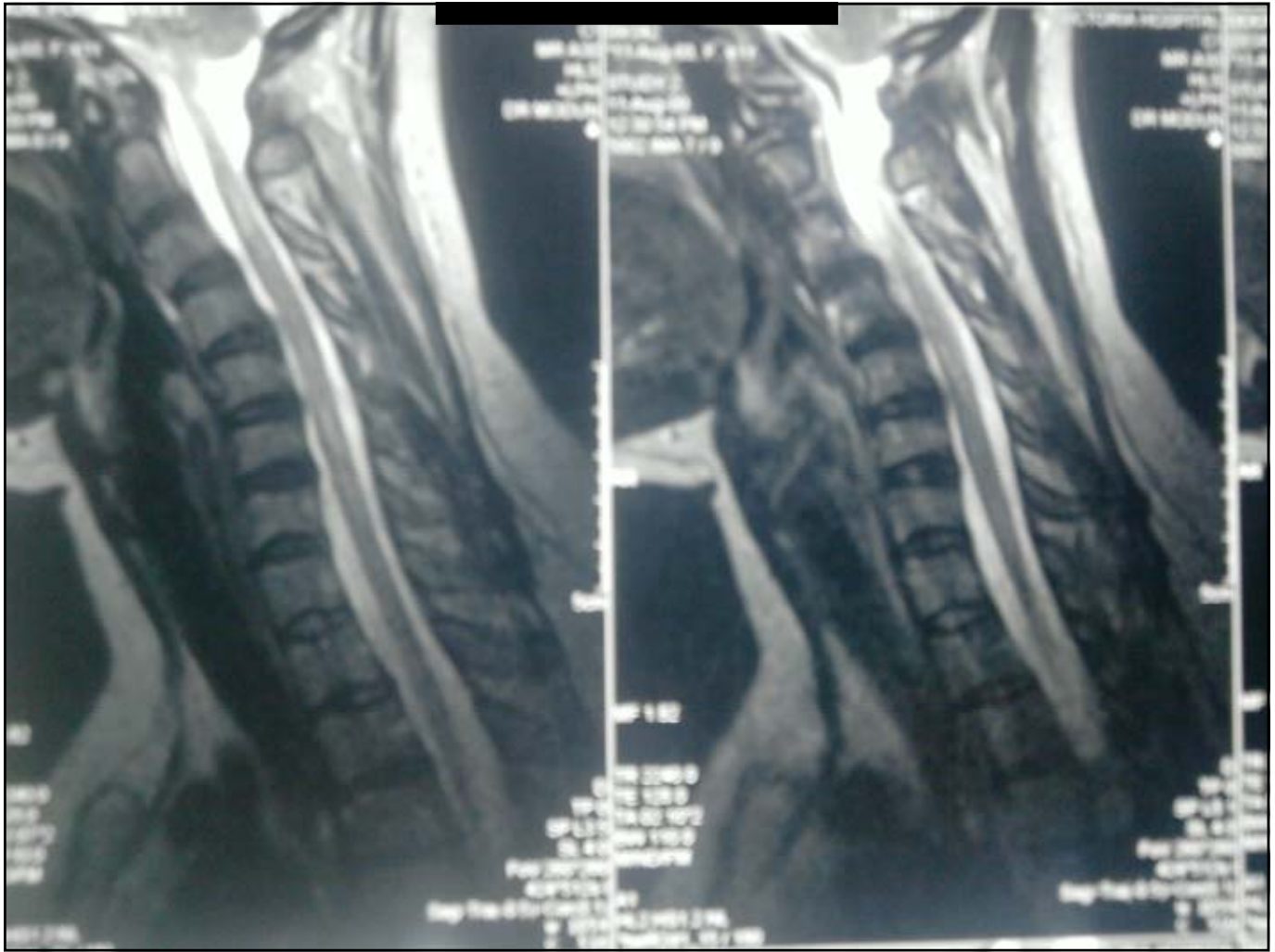Clinical Case 3

- Mrs P.D.
- Attended with walking difficulty
- Consultation with Orthopedic Surgeon
- MRI Lumbosacral area... NAD
- Proposed arthroscopy both knees
- Came to me for 2nd opinion
- Noted: - spasticity b/l lower limbs
 - increased tendon reflex
 - no sensory deficit

Clinical Case 3...

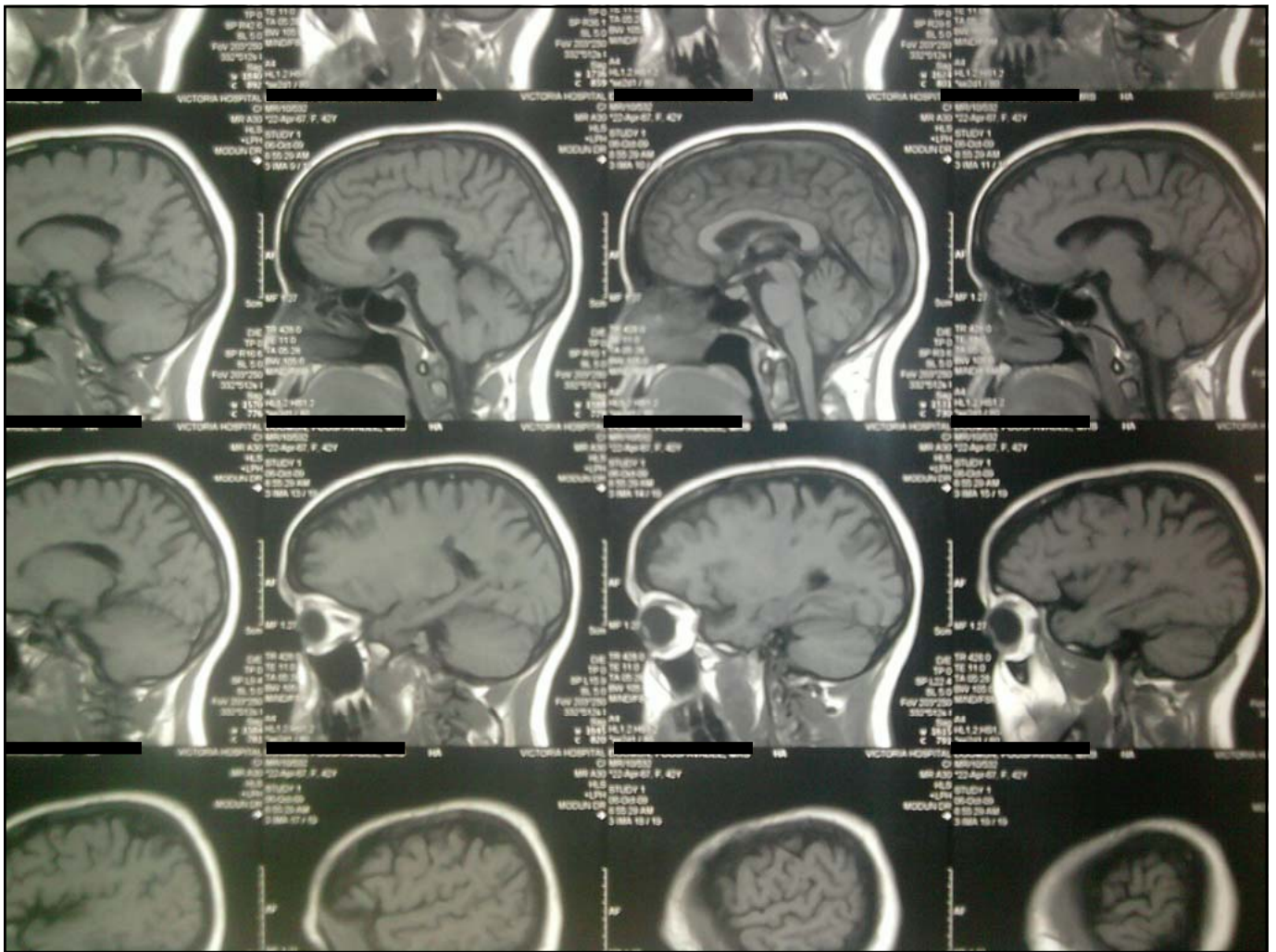
- Referred to Neurologist Dr Lam for confirmation of findings
- MRI thoracic region

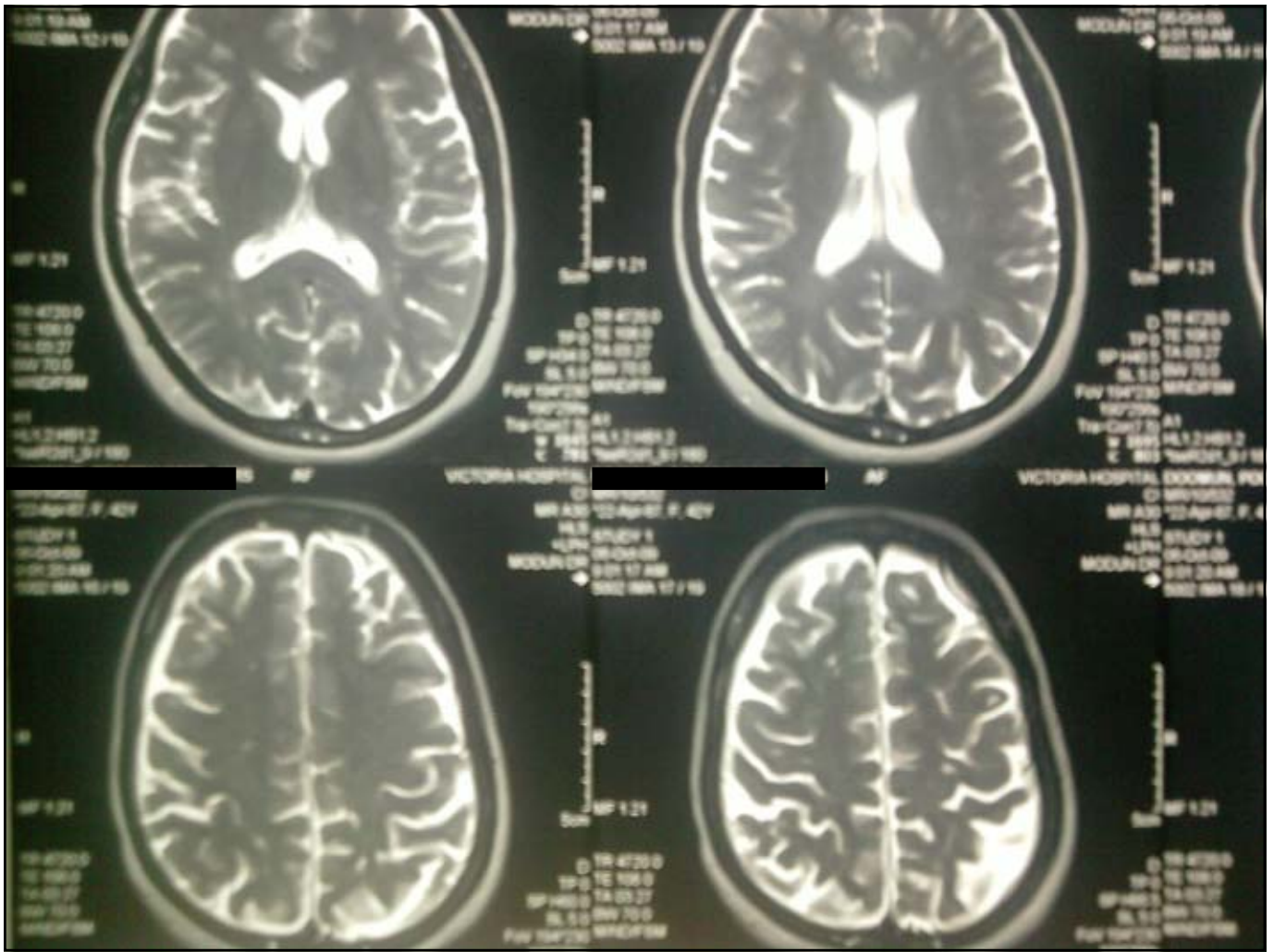


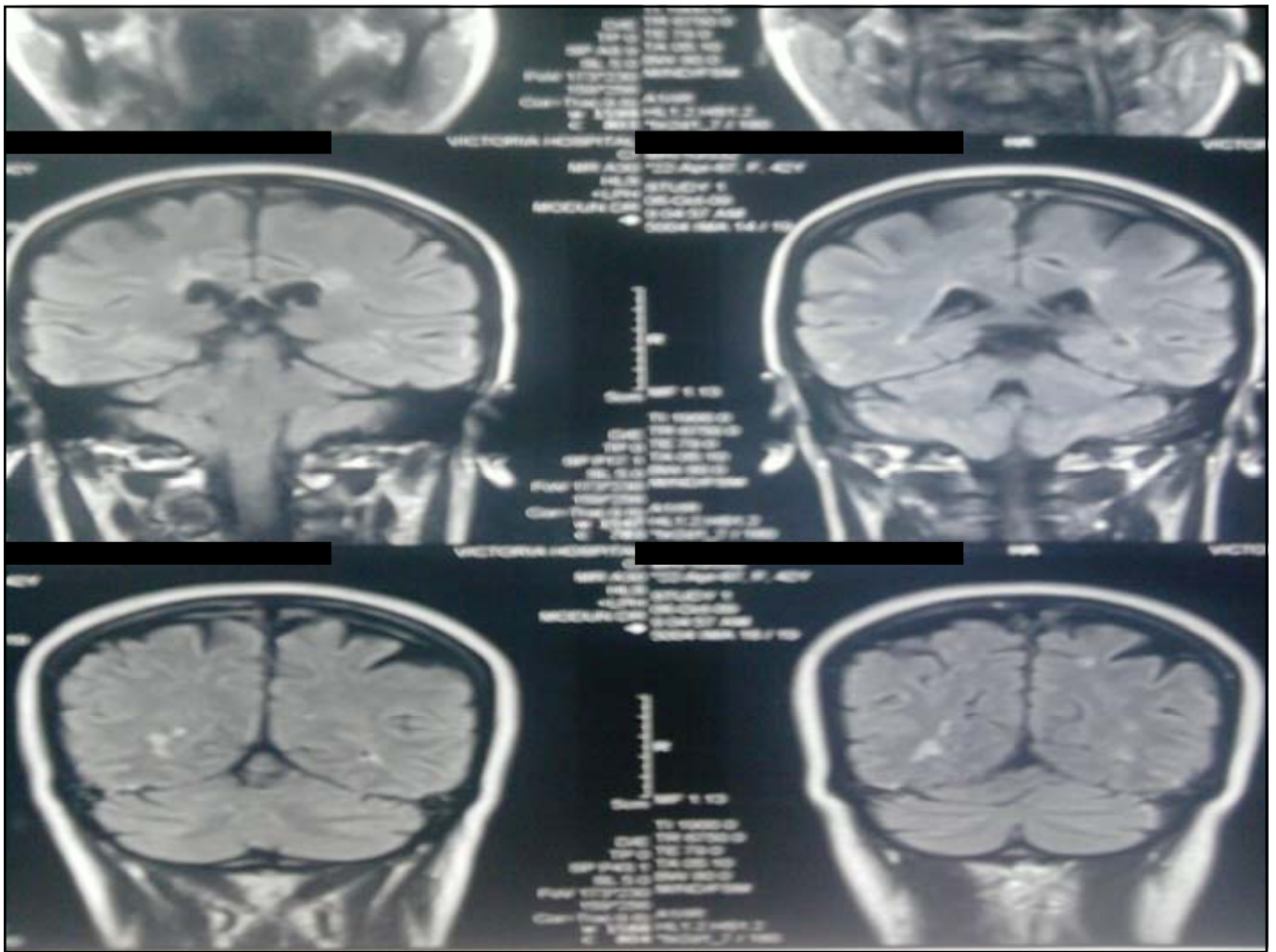


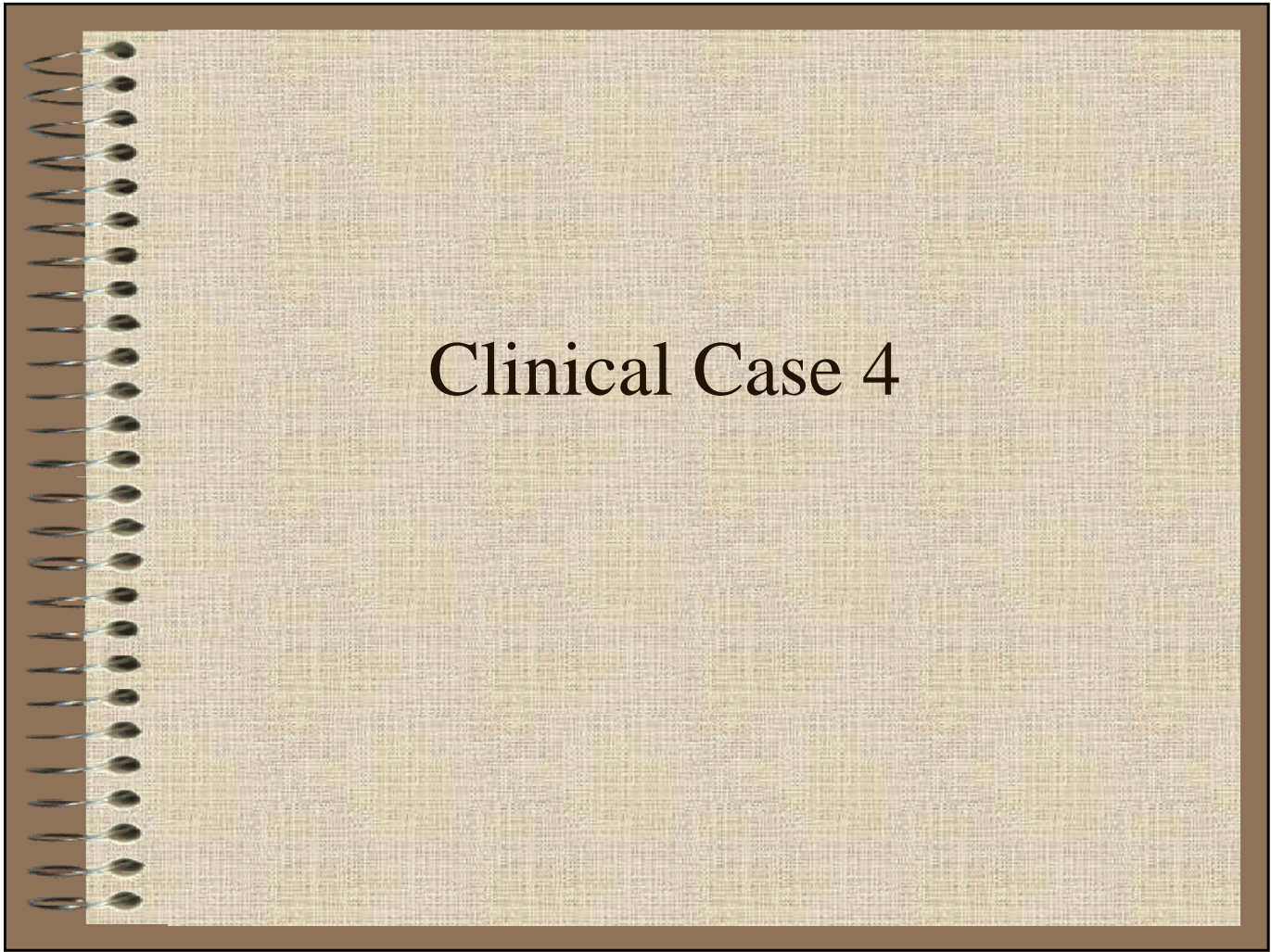
Clinical Case 3...

- Contacted Dr Lam again
- MRI Brain requested...



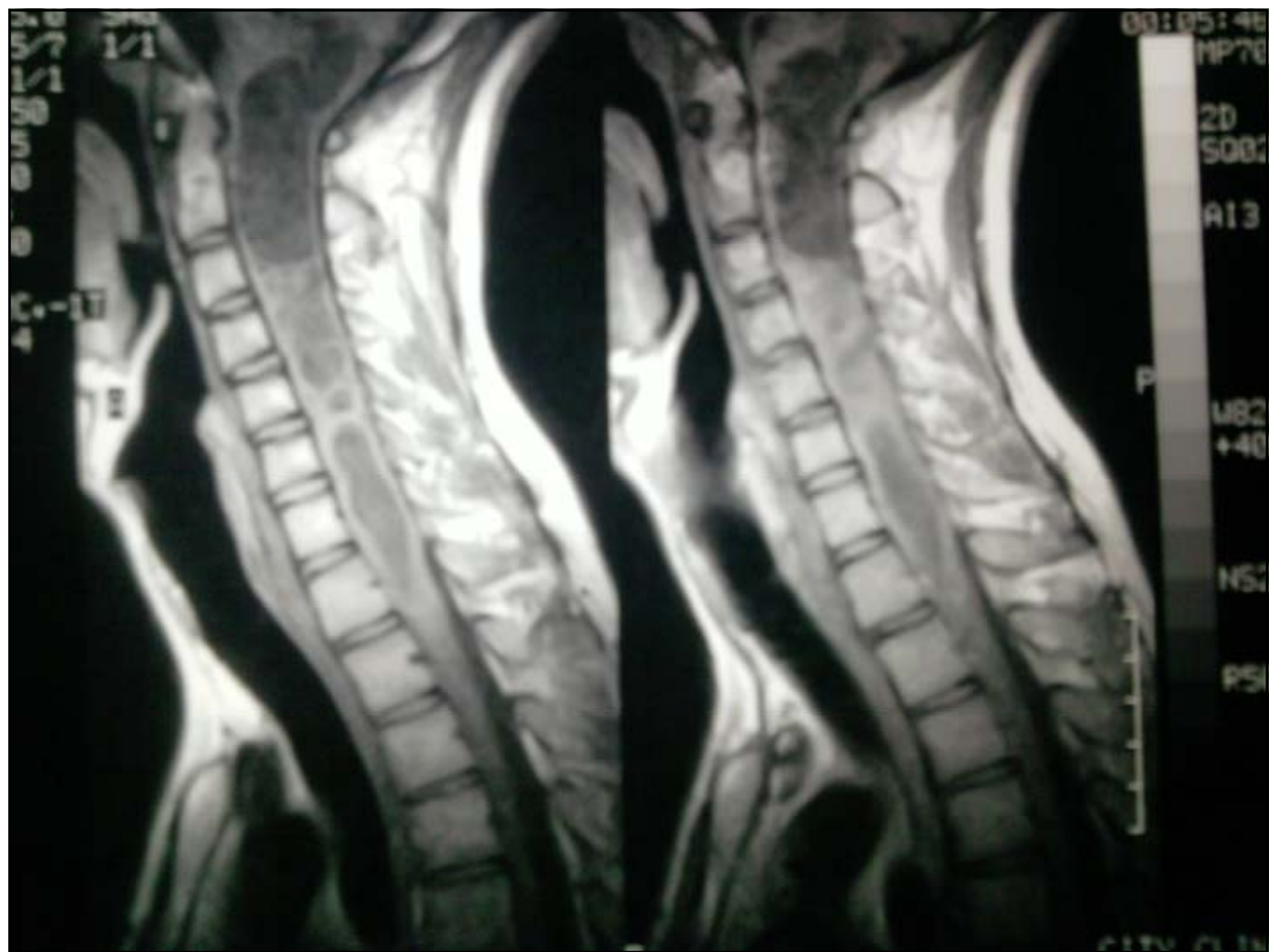


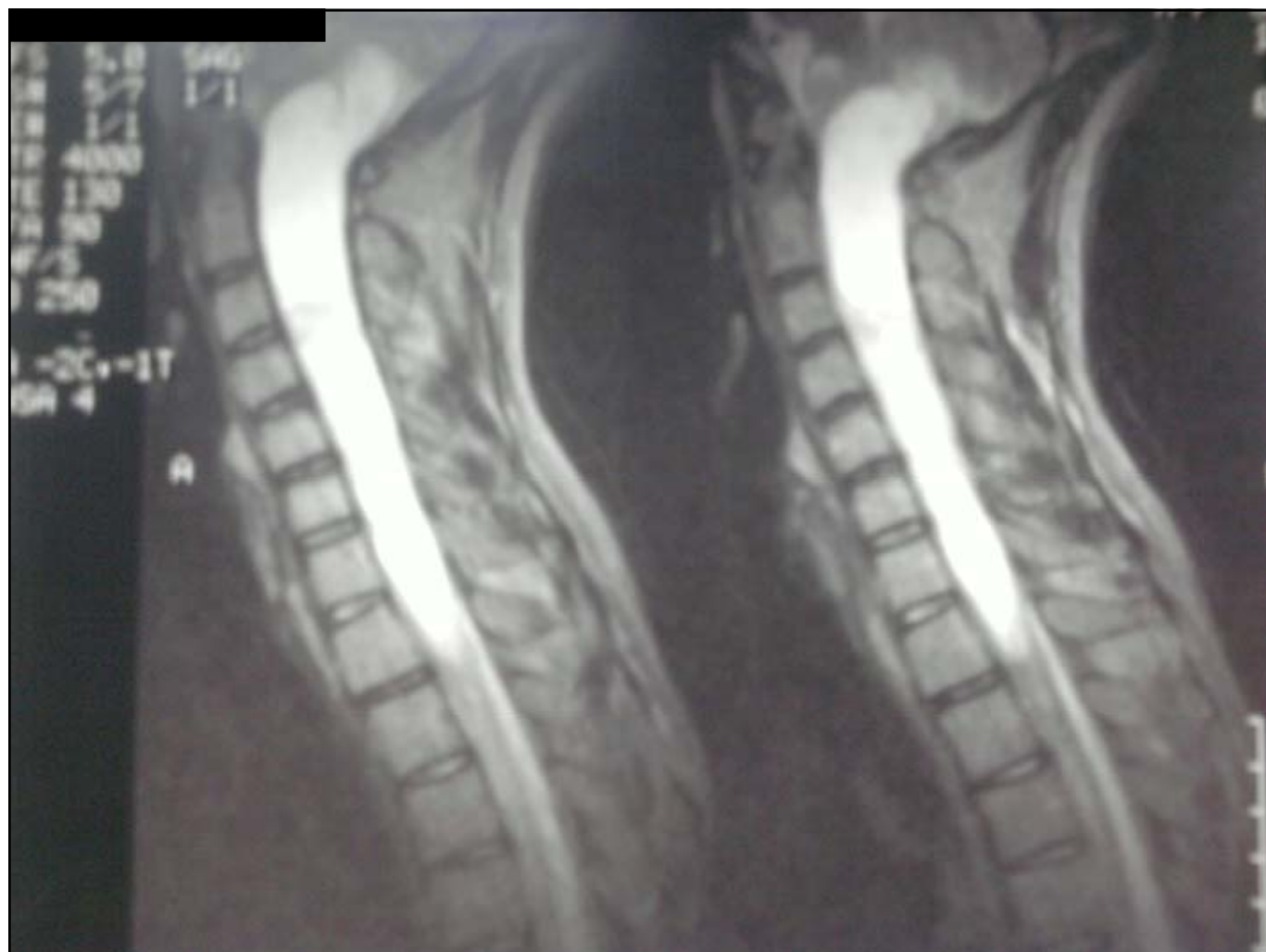
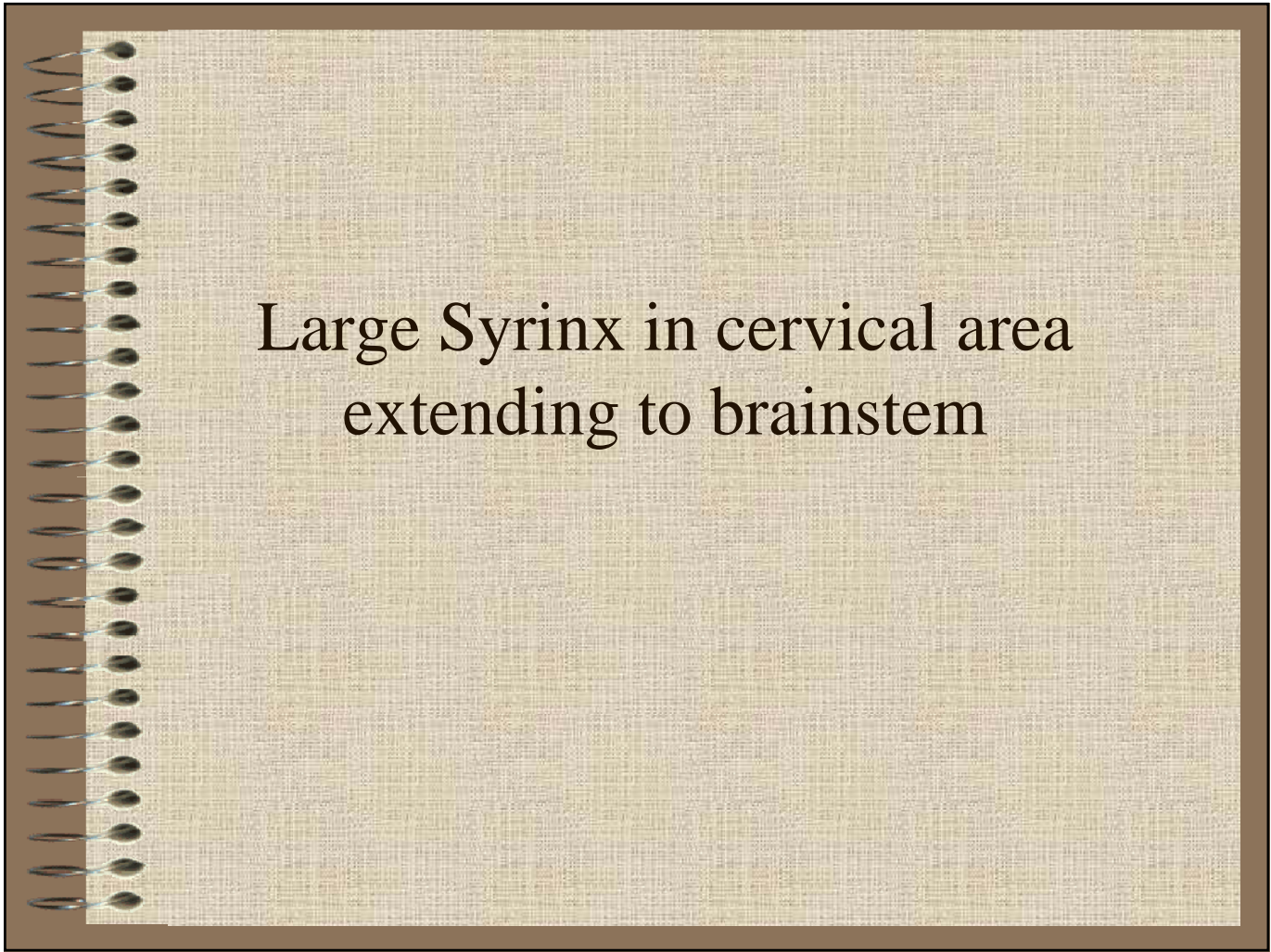


Clinical Case 4

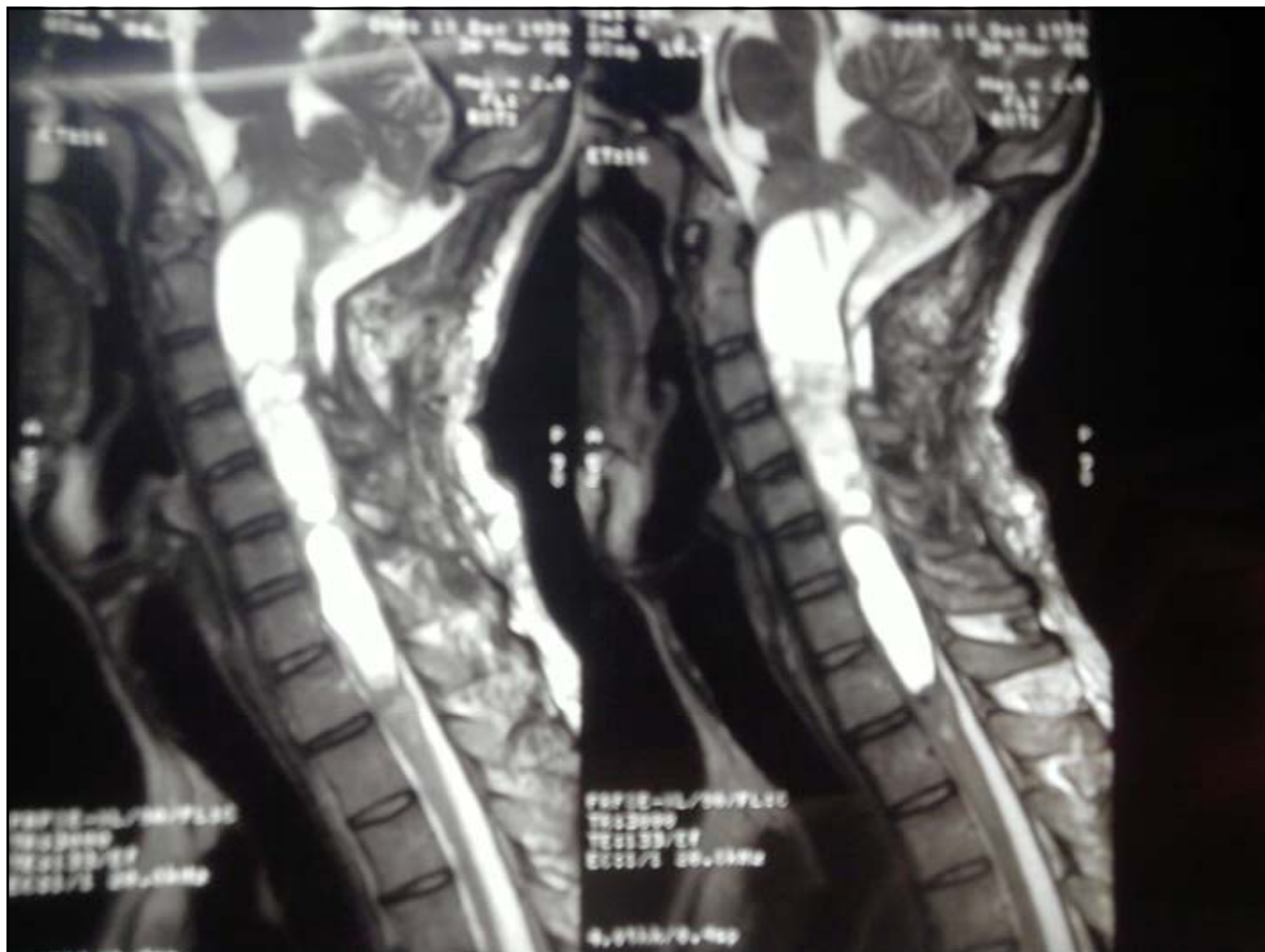- Mr P, 22 years
- University Student
- Complaining of cervical pain for the past 2 years
- Has been attending chiropractor regularly
- Presented to Orthopedic Surgeon with worsening pain
- MRI cervical spine requested
- Developed tetraparesis by the time he came to me





A spiral-bound notebook with a textured, light brown cover. The spiral binding is on the left side. The text is centered on the cover.

Large Syrinx in cervical area
extending to brainstem



Clinical Case 4...

- Operation:
- Posterior fossa decompression
- Shunt from syrinx to subarachnoid space





