

Non Surgical Management of Back pain.

Dr Pankaj Wadhwa

MBBS,MD(Anaesth),DNB,Dip.Acu,
FIPP, Fellowship in Pain Management.



MAGNITUDE OF THE PROBLEM

- It is one of the commonest experiences of humankind.
- It affects 60-80% of the adult population in USA.
- Point prevalence is 30% in USA.
- It is probably experienced by nearly everyone at some point in his or her life.

Interventional Pain management

Interventions are Minimally Invasive, Non Surgical and Target Specific procedures to Diagnose and to treat Various painful conditions

It fills the gap between pharmacologic management of pain & more invasive operative procedure

CAUSES OF BACK PAIN

Major causes

1. Facet joint arthropathy
2. Disc disruption/Discogenic Pain
3. Sacro-I liac joint arthropathy
4. Disc prolapse/ herniated disc/ slipped disc
5. CRPS/ RSD

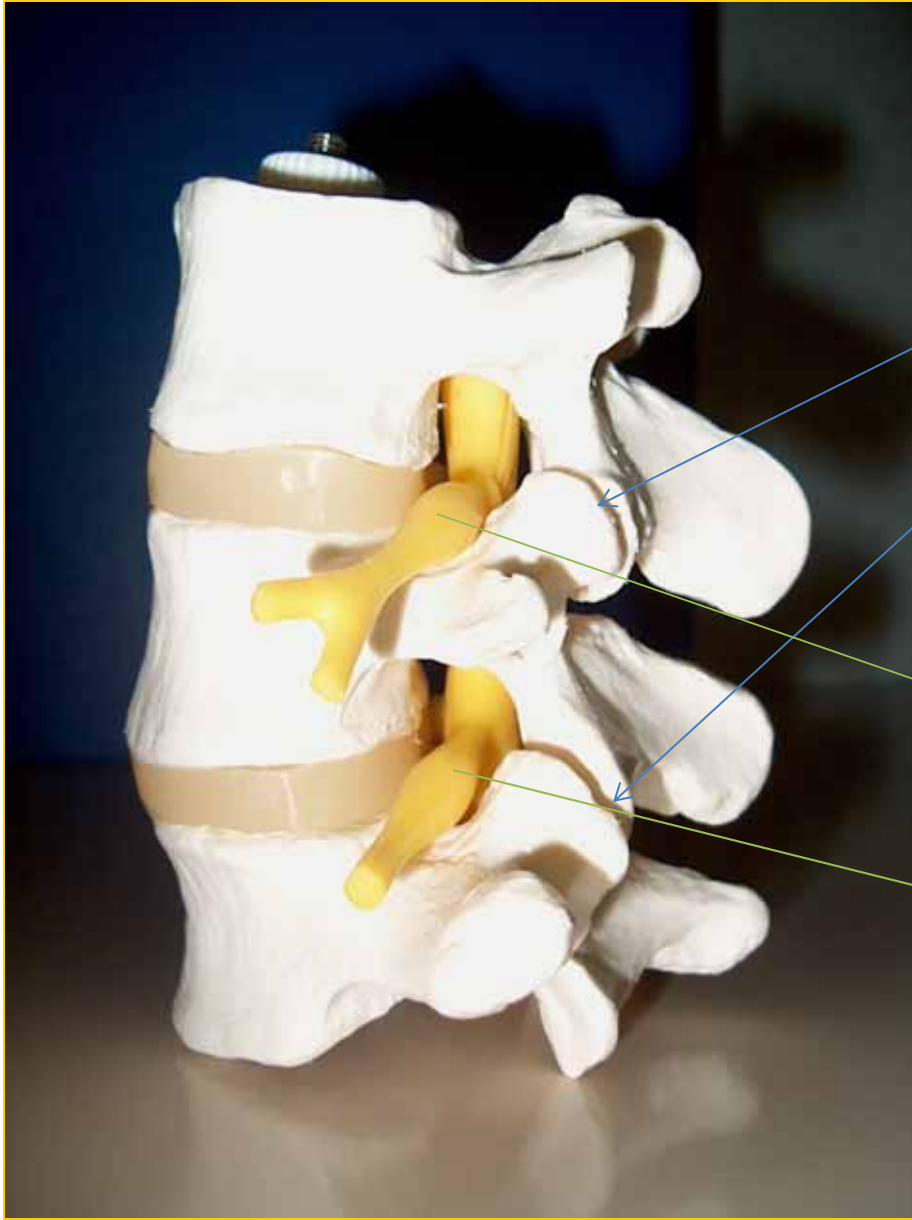

Facet Joint Pain

Low back pain- unilateral or bilateral

(Facet joints responsible for spinal pain in 15% to 45% of patients with low back pain)

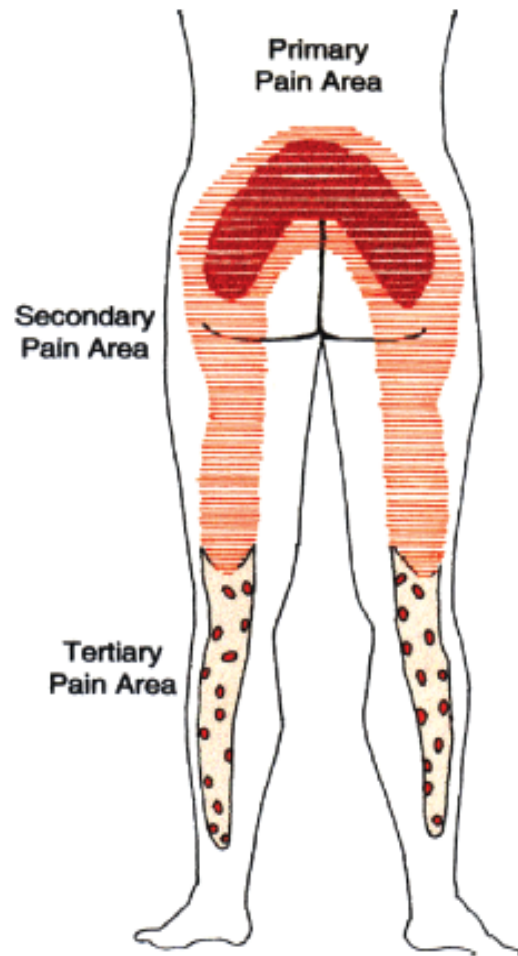
- Referred to the buttocks, groin, hip, or posterior and lateral thigh.
- Pain is more prominent in the morning and with inactivity
- May aggravate on extension after forward flexion
- Tenderness over facet joints



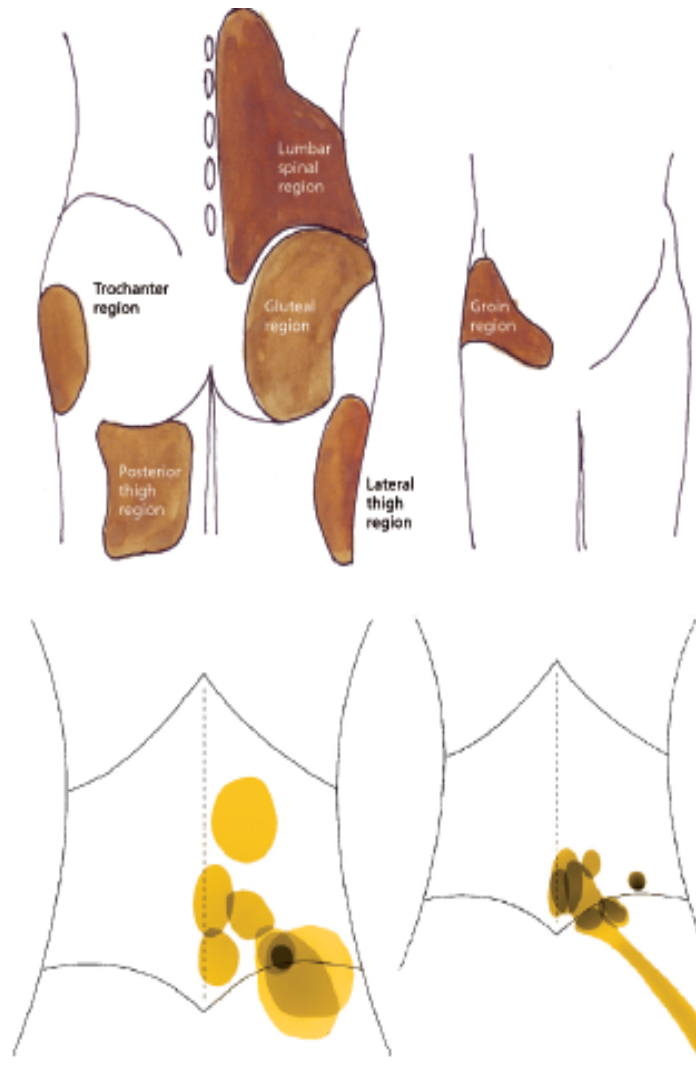
- FACET JOINTS

SPINAL NERVES

PAIN DISTRIBUTION



A. Illustration of distribution of lumbar facet joint pain.⁵

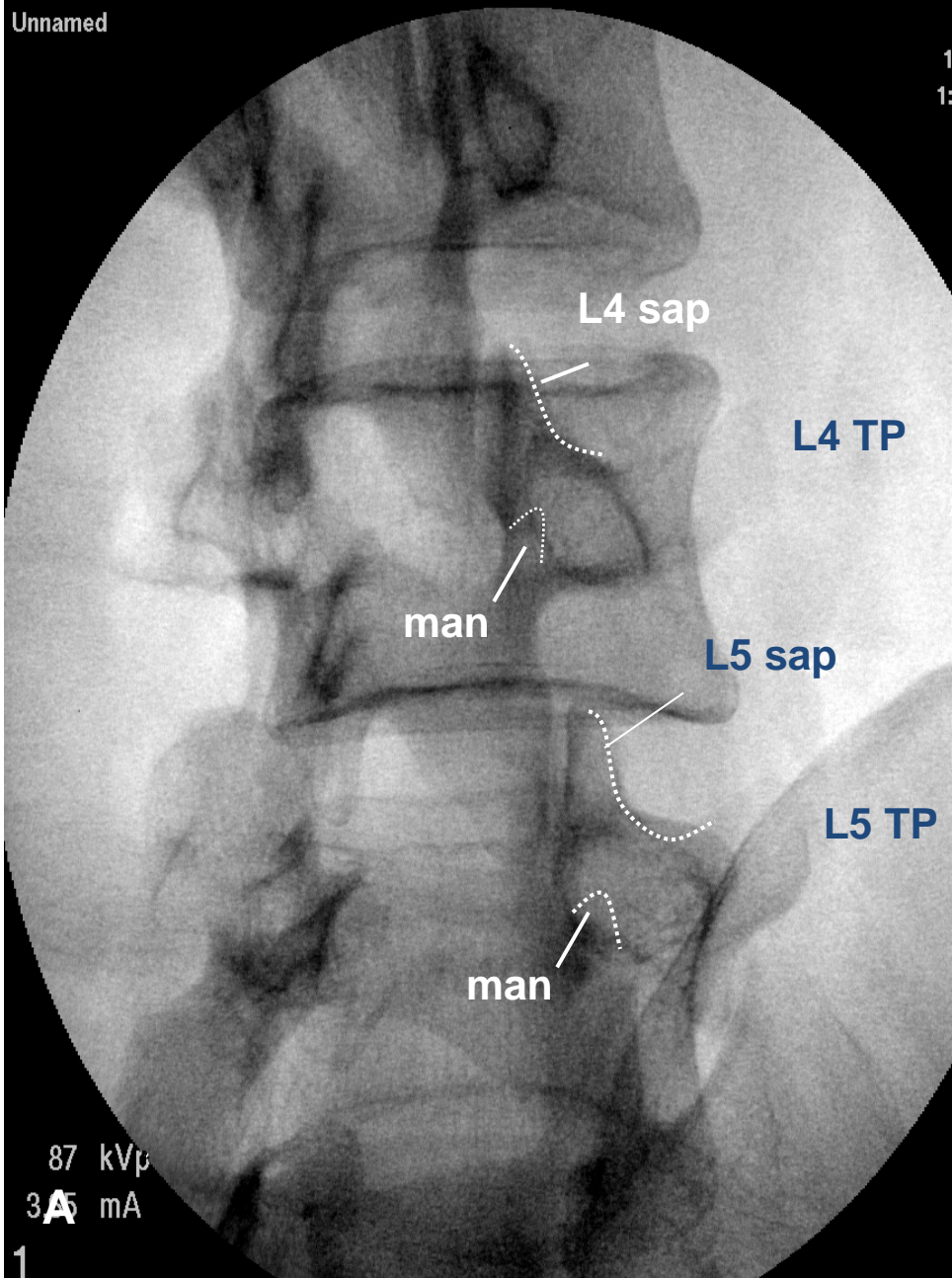


B. Referred pain distribution.

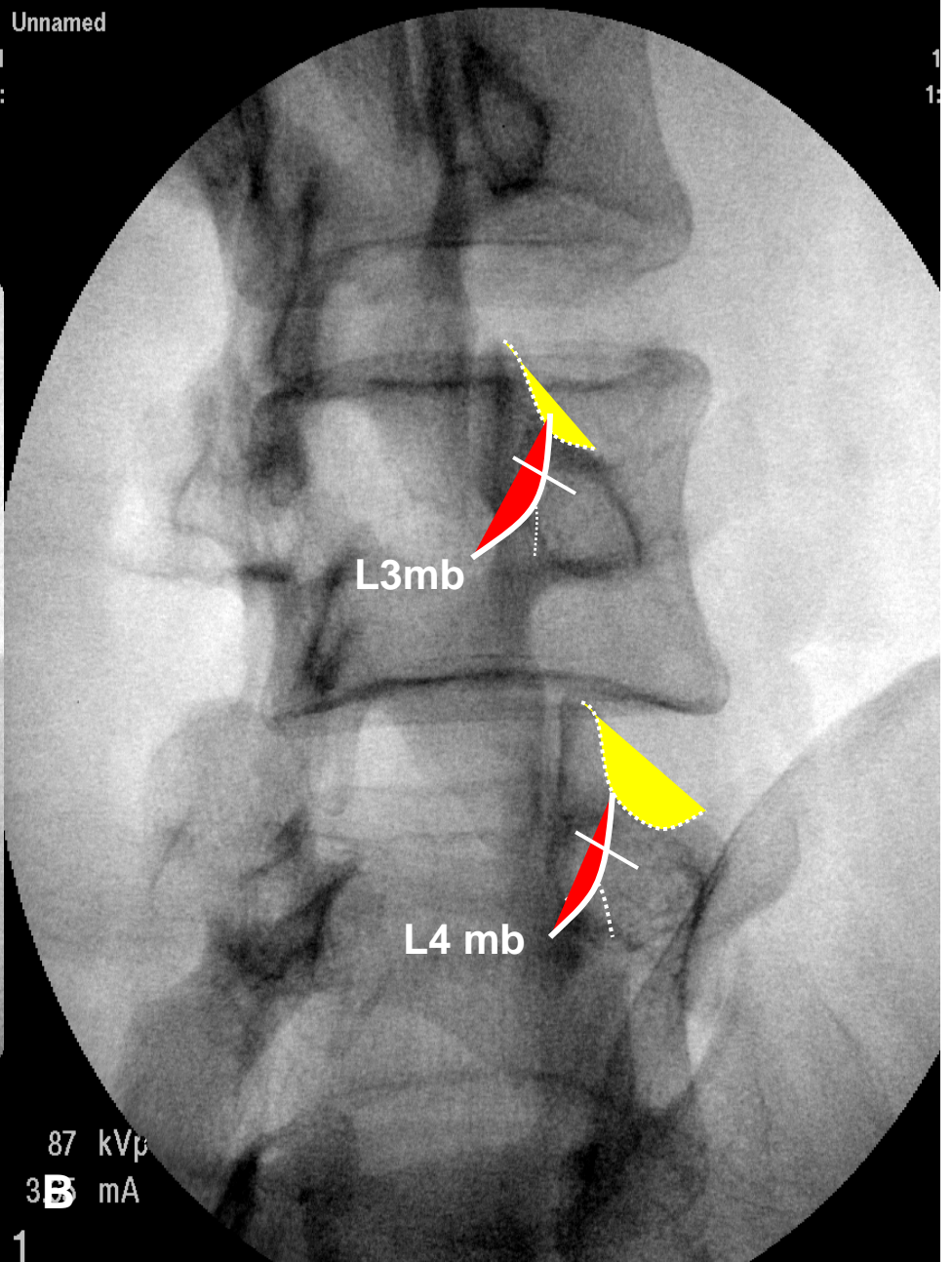
- 1 – lumbar spinal region;
- 2 – gluteal region;
- 3 – trochanter region;
- 4 – lateral thigh region;
- 5 – posterior thigh region;
- 6 – groin region.⁸

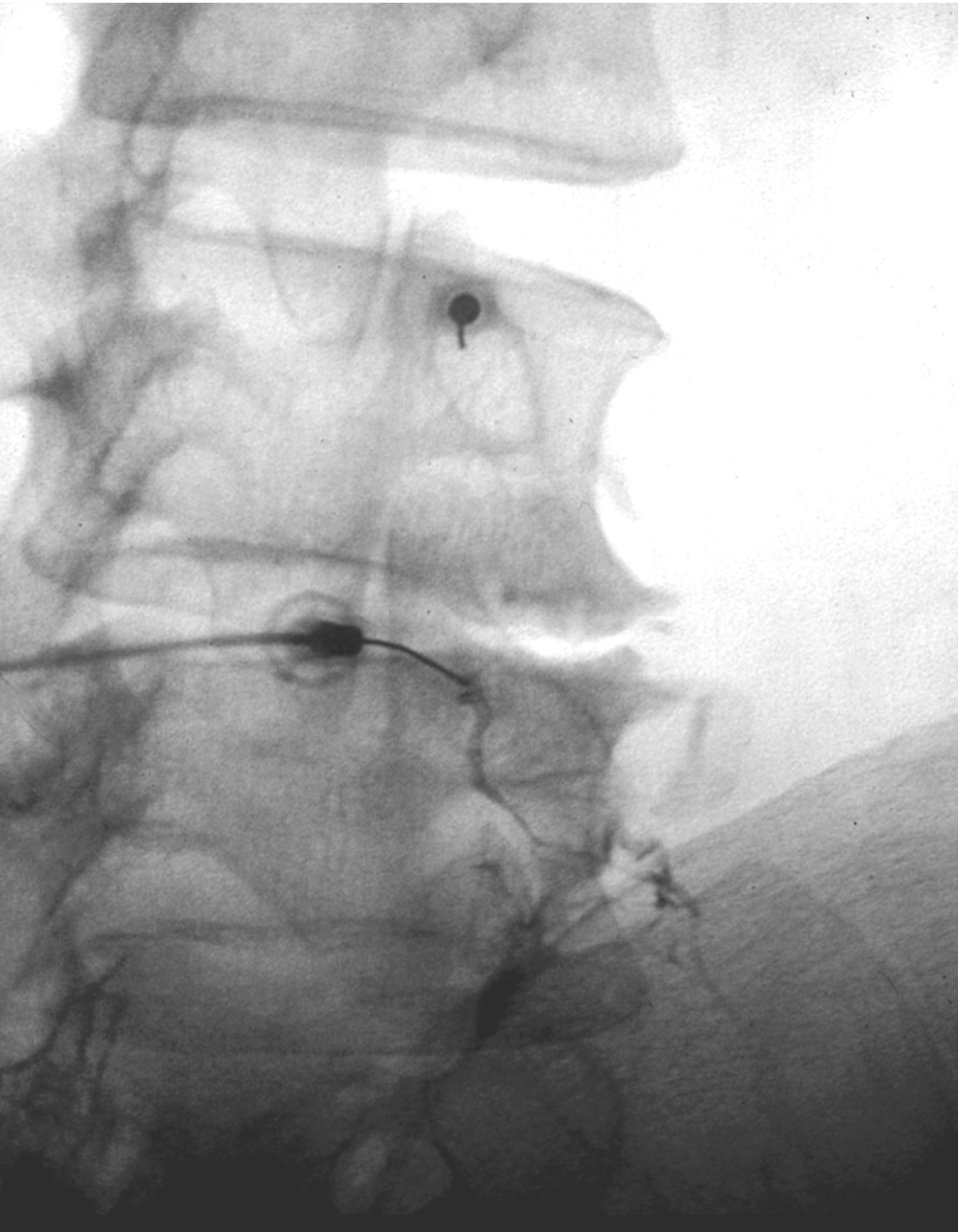
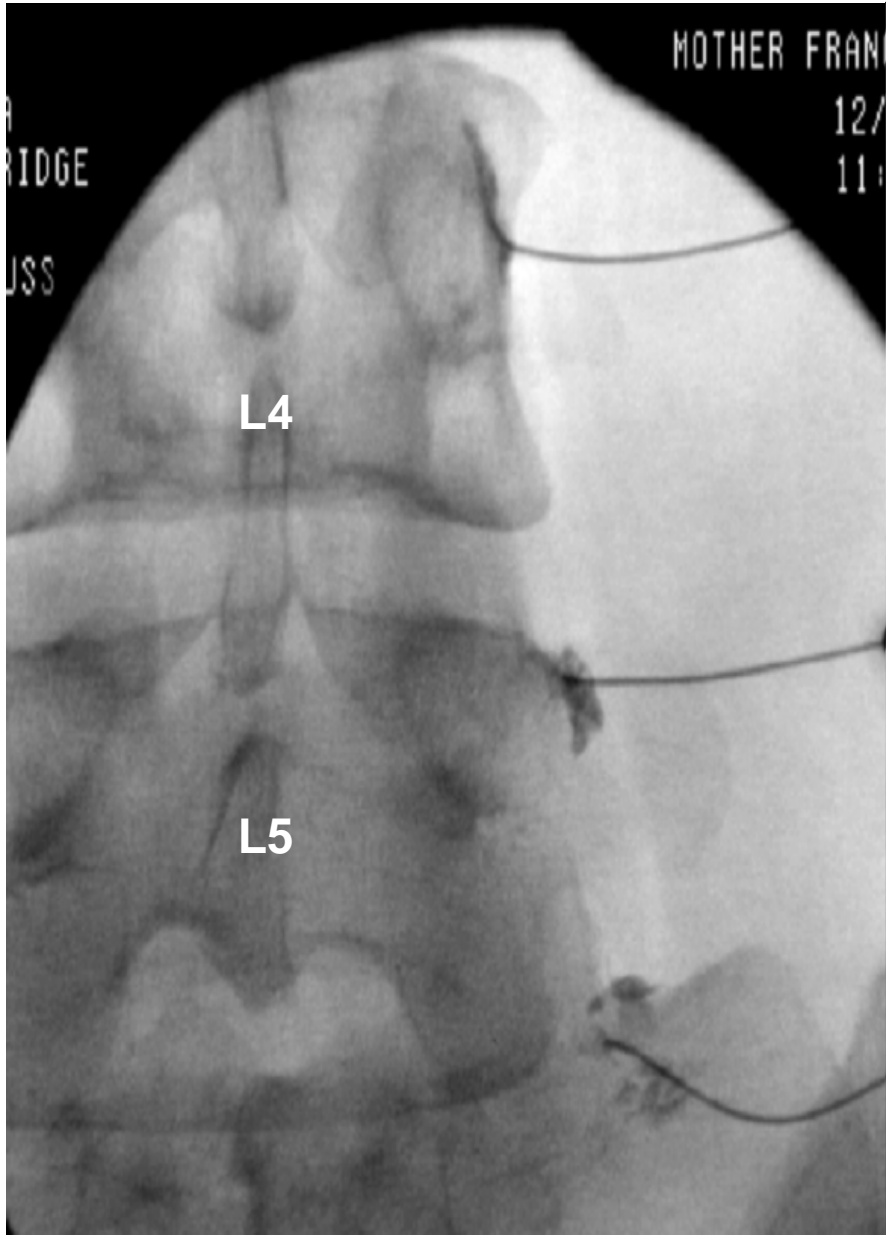
C. Composite drawing of the referral zones of all 8 subjects derived from the minimal threshold stimulation of their right L3 (left) and right L4 (right) medial branches.⁹

Unnamed



Unnamed



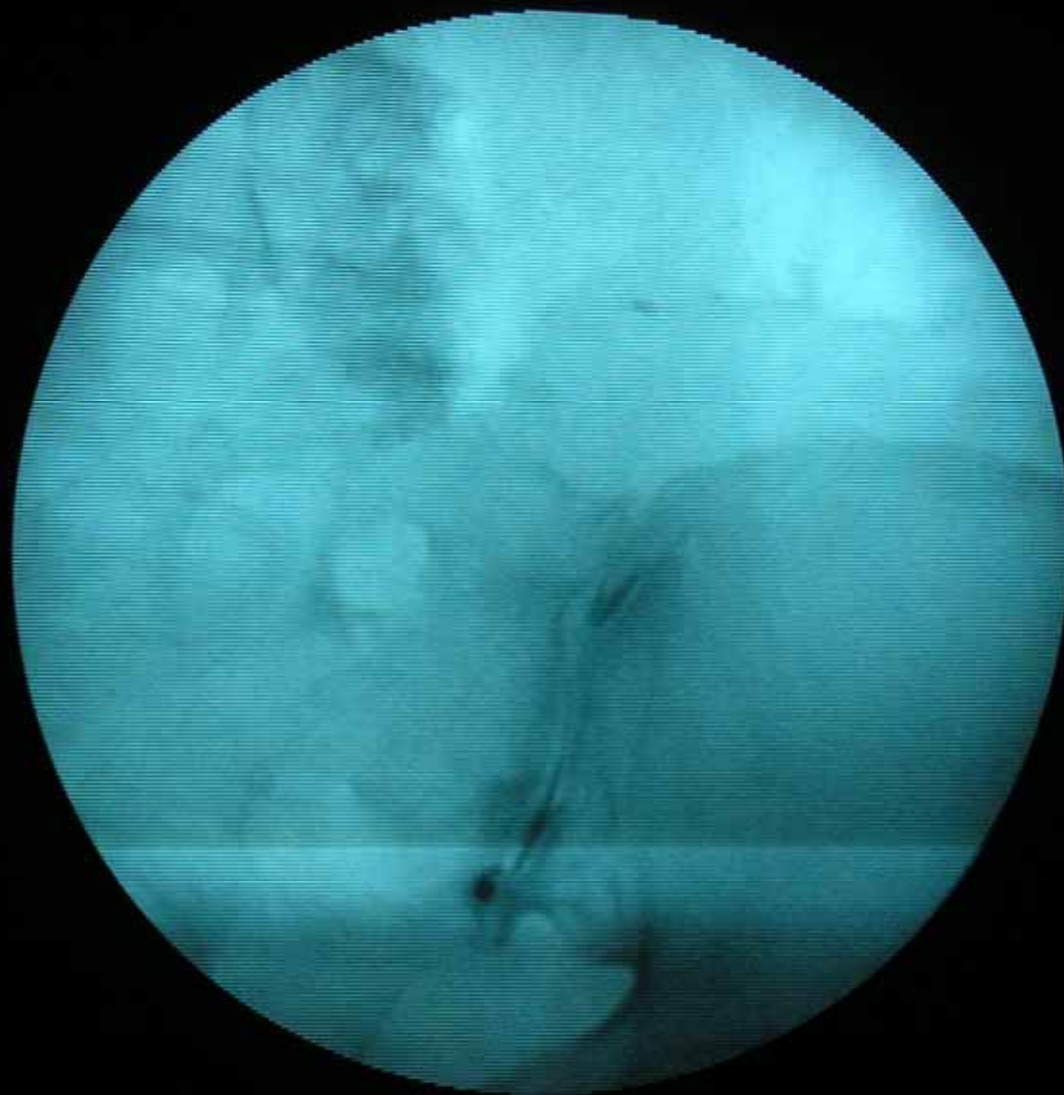


Radiofrequency Ablation

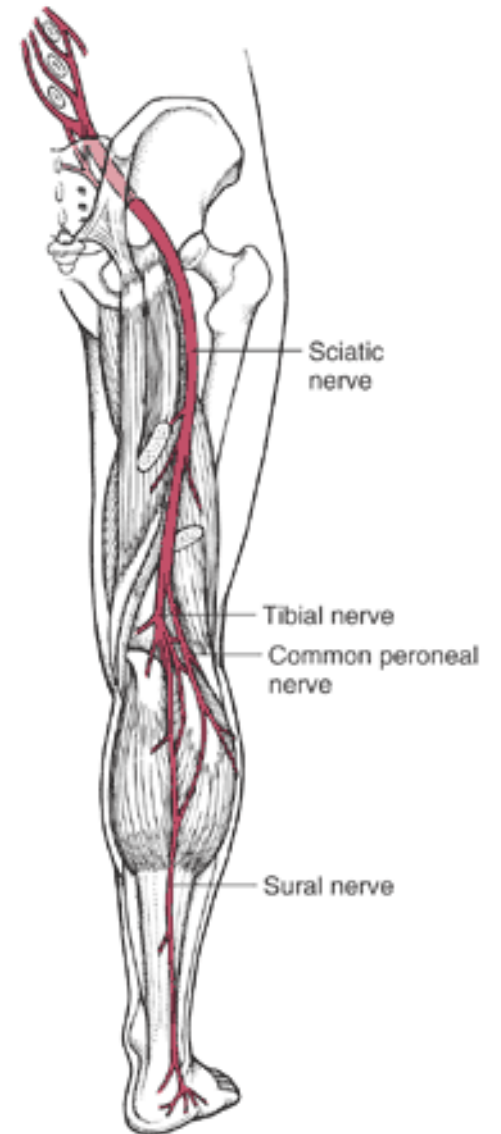
- Strong evidence for short term relief (6-12mths)
- Moderate evidence for long term pain relief(5-7 yrs)
- Excellent and probably only tool for managing facet joint pain
- Easy repeatability
- Day care

SI joint Block/ Radio-Frequency Rhizotomy

- SI joint is responsible for at least 13% and perhaps as high as 30% of Low Back Pain.
- Percutaneous radiofrequency neurotomy of sacroiliac joints or steroid injection into SI joint provide long-term relief

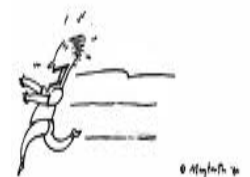

**DISC PROLAPSE/
HERNIATED DISC/
SLIPPED DISC**

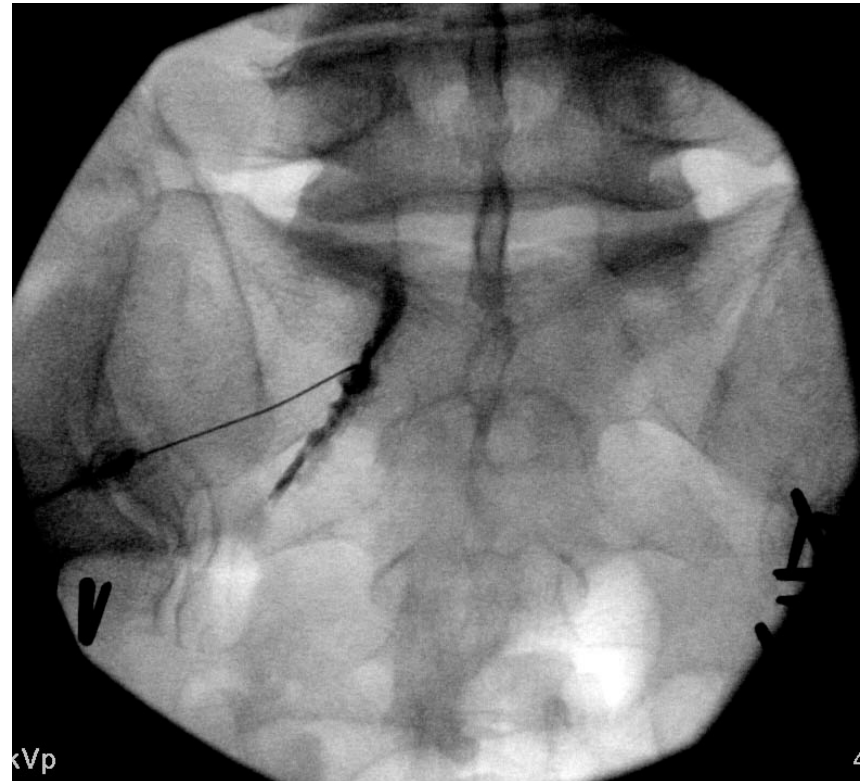
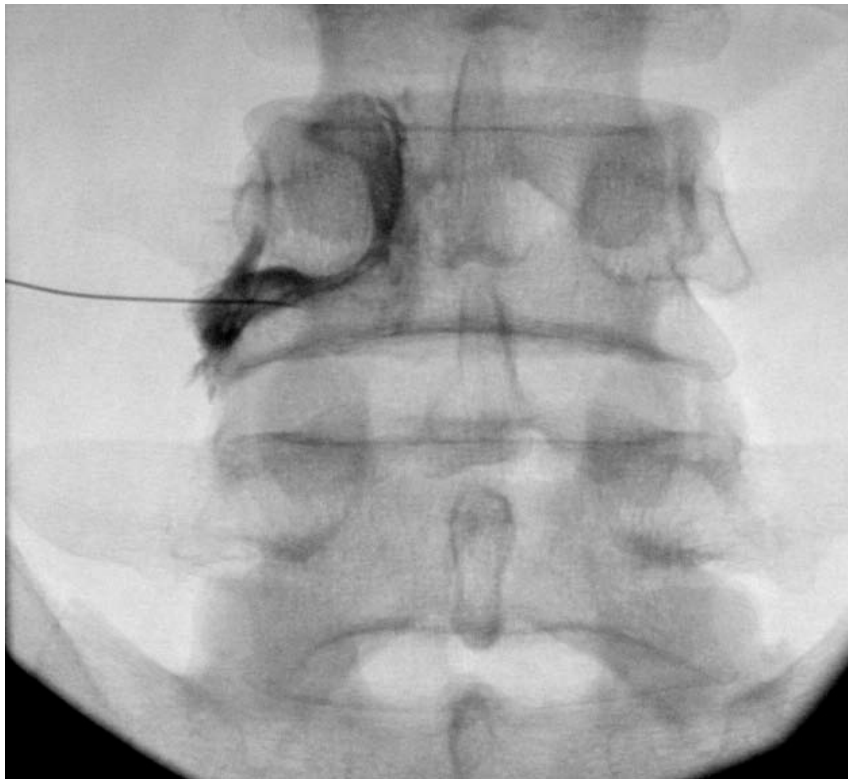

Selective nerve root/ Transforaminal epidural block

- Diagnostic as well as therapeutic purpose.
- Therapeutically it is more effective than ESI.
- 10-20mg vs. 40-80 mg in lumbar epidural.
- If there is epidural scar as in FBSS it is the only route.



Transforaminal



Transforaminal Steroids Efficacy

- Lumbar radicular pain
 - » Confirmed HNP by MRI
- LSE without benefit
- On surgery schedule

- 75% excellent relief up to 10 years

- Average ~2 transforaminal injections

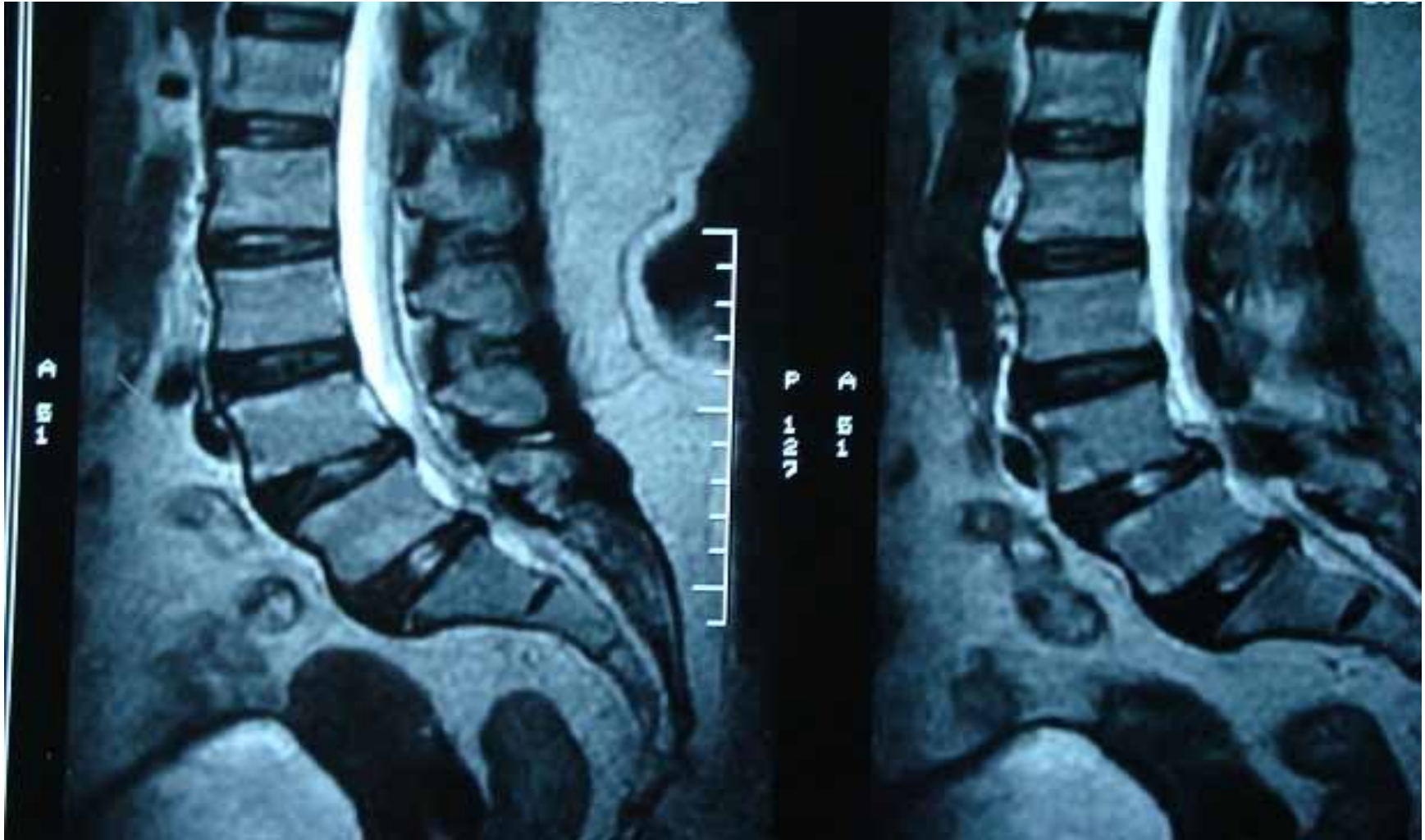- Riew *et al*, *J Bone Jt Surg (Am)*, 2000
 - Vad *et al*, *Spine* 27:11-16, 2002



Percutaneous Disc Decompression/Discectomy

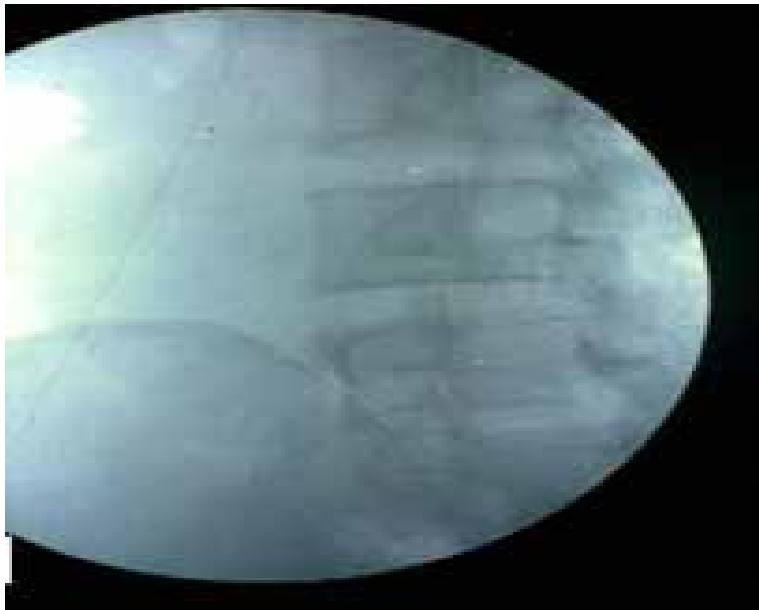
- It is done for disc prolapse & discogenic pain.
- Here a 17G needle introduced into the diseased disc under C-arm guidance.
- Then a special motorized probe is introduced through this needle & operated.
- It breaks the nucleus pulposus into fine particles and sucks it out.

Disc Herniation

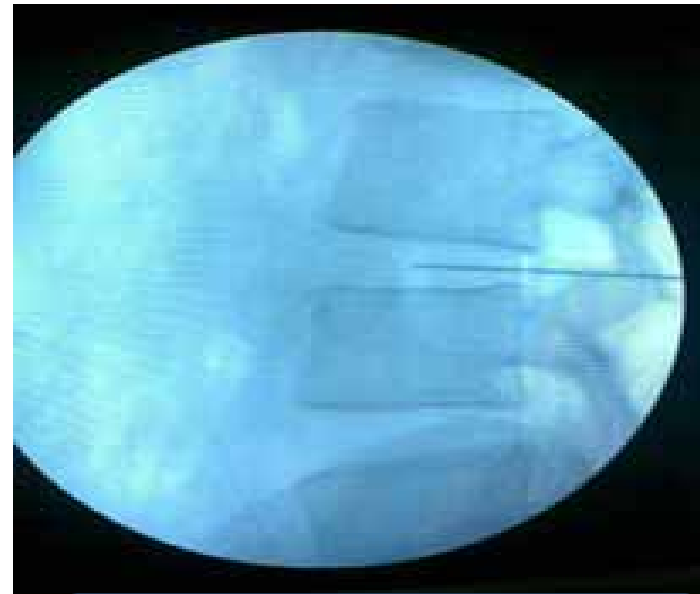

Management : Disc Herniation

Percutaneous Partial discectomy +Ozonucleolysis

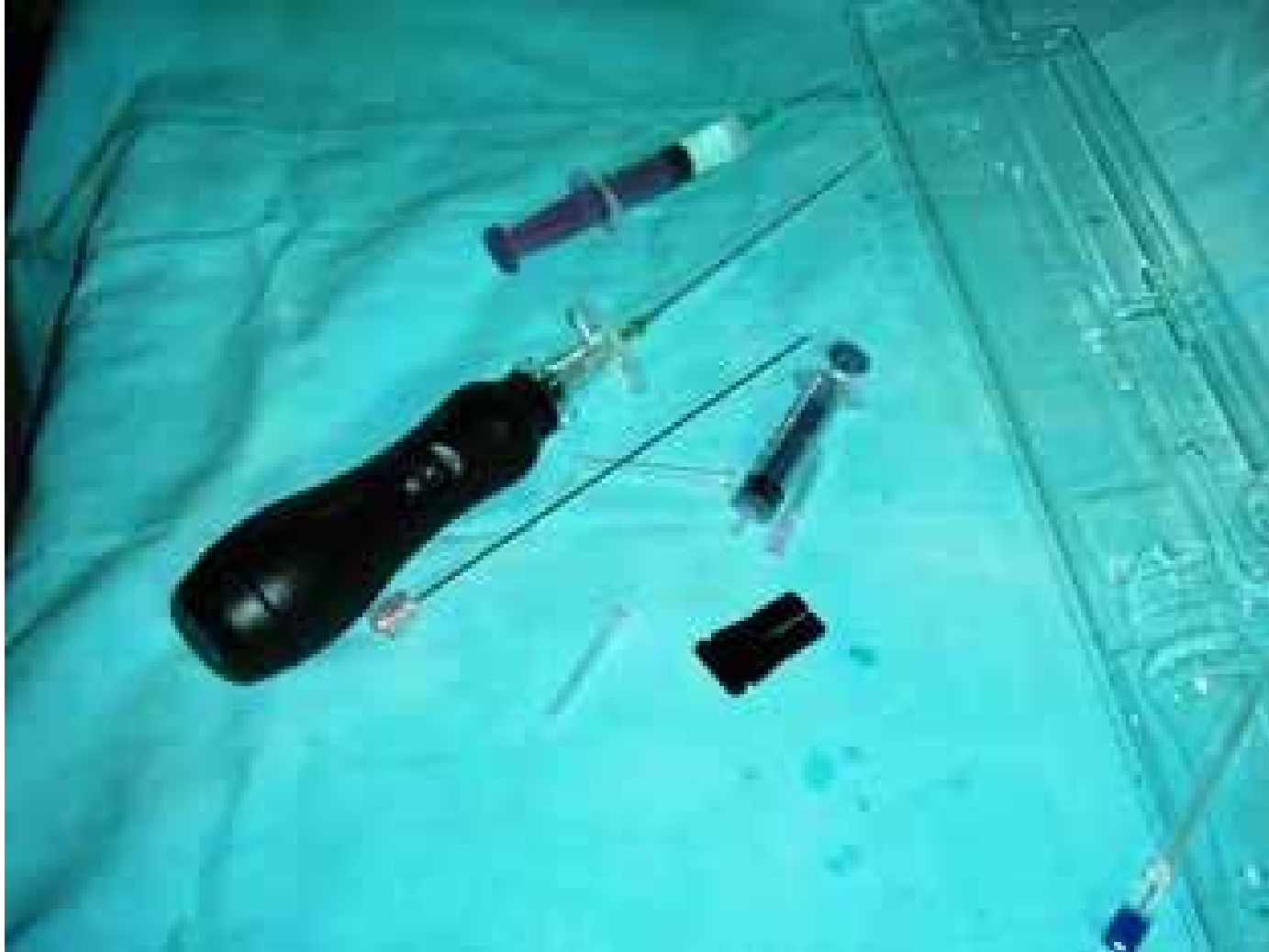

Under fluoroscopic Guidance
Correct level of the prolapsed
disc is identified

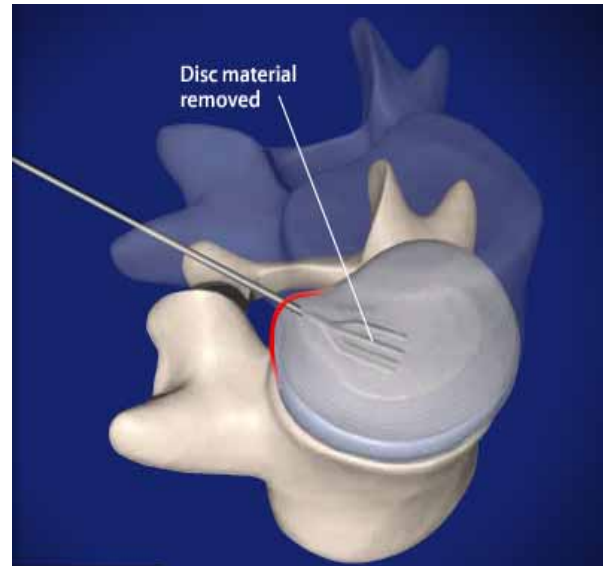
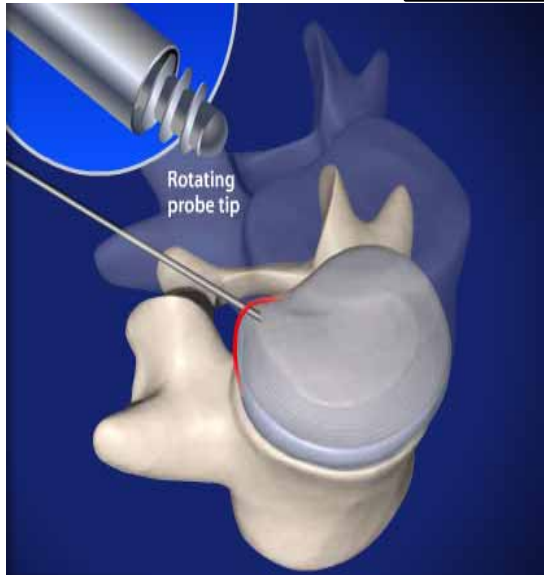


Needle is inserted into the centre
of the Disc and decompressor is
placed thro the needle.

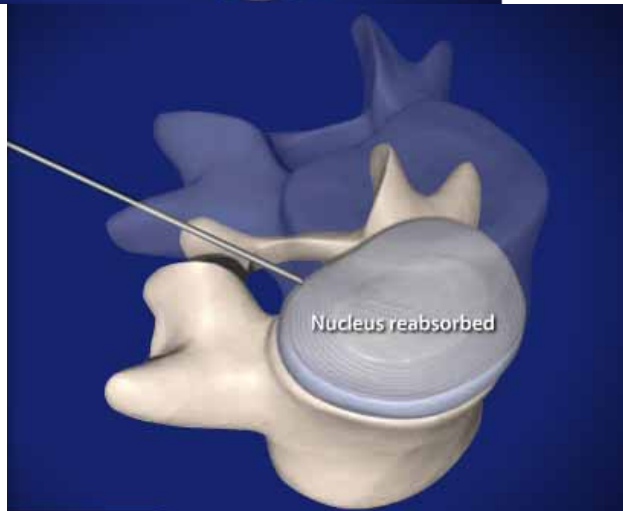Decompressor



Percutaneous Disc Decompression



Rotating tip removes small portion of disc material. Because only enough of the disc is removed to reduce pressure inside the disc, the spine remains stable.



Insertion site covered with bandage.

Recovery is fast as unlike surgical decompression no bone or muscle is cut.

2-3 days of bed rest and may return to normal activity within one week.



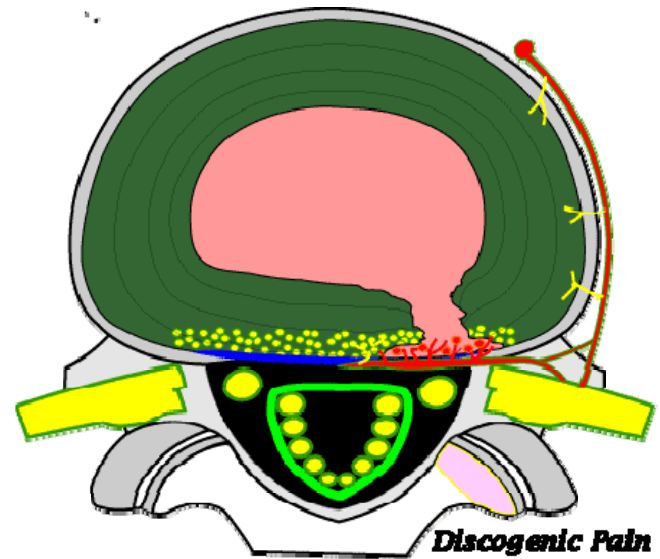
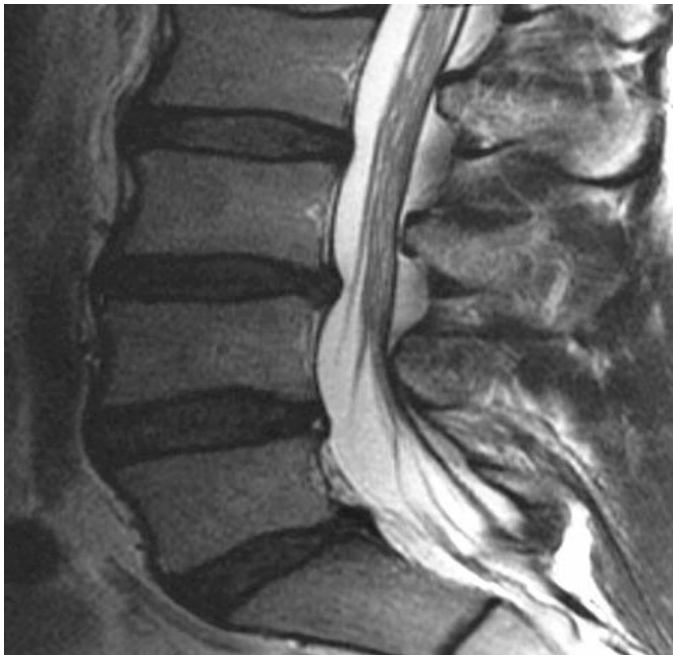Ozone Nucleolysis (Ozonucleolysis)

- It is a technique of injection of ozone in the disc that brings about a physical shrinkage and reversal of vascular, chemical and biohumoral events that occur in disc herniation and cause radiculopathy
- Needs three to four sessions.

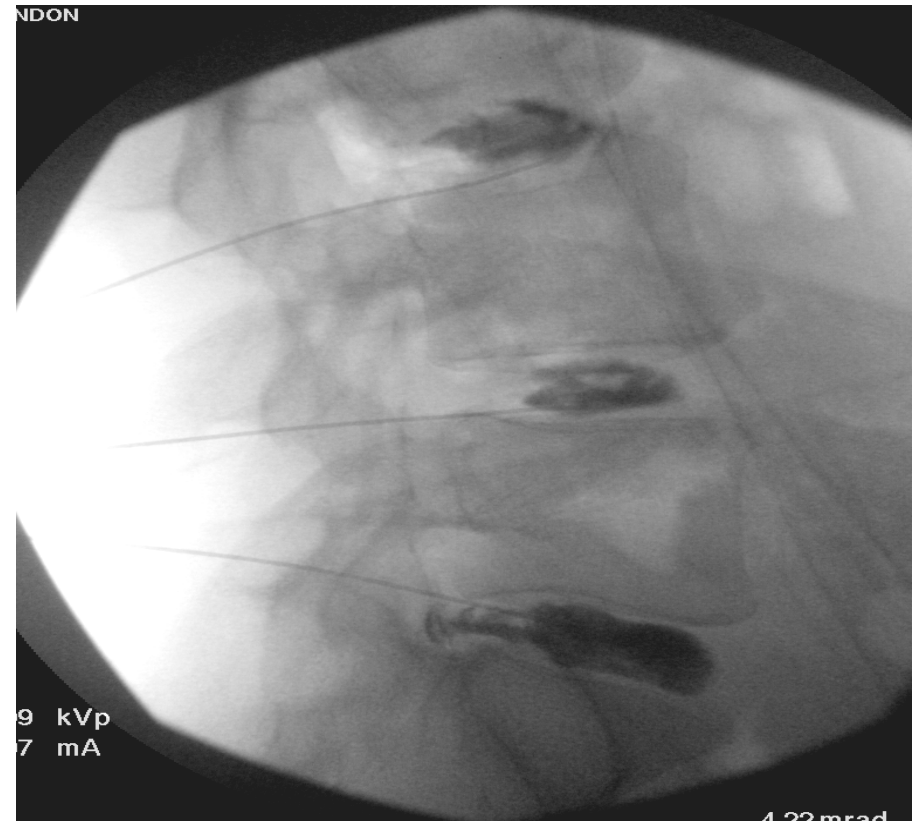
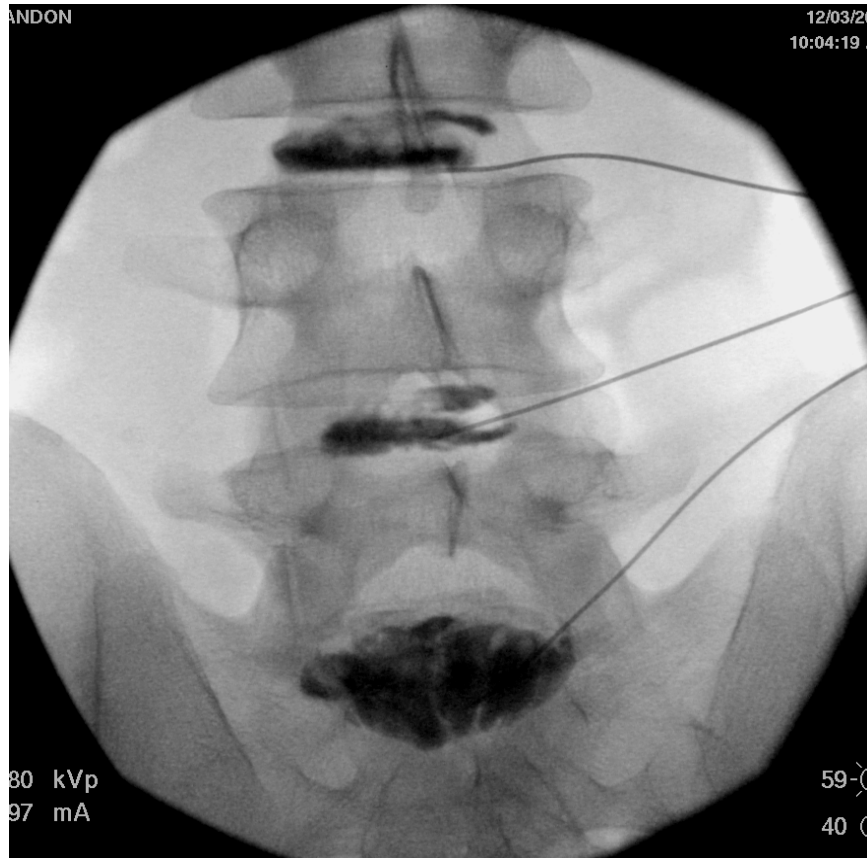PDD: advantages

- Success rate 80%(Sharps and Issac 2002),
- No cut, scar,
- No epidural fibrosis,
- Stability of normal anatomical structure is maintained.
- Hospital stay is less and less costly.

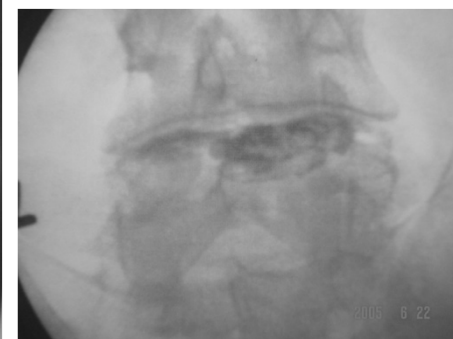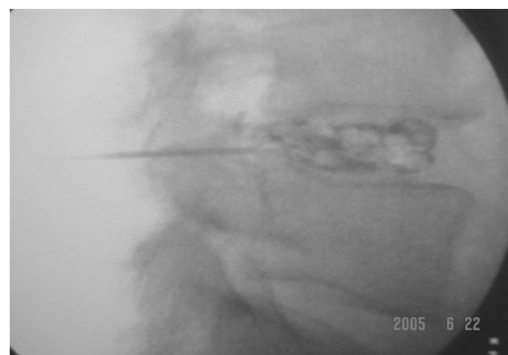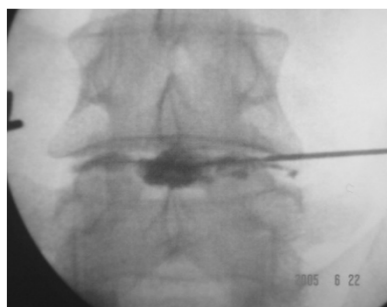
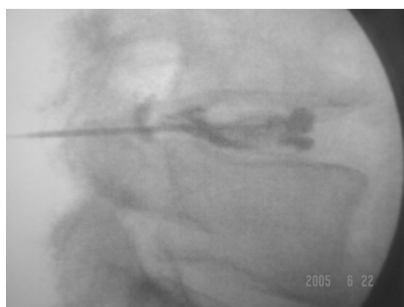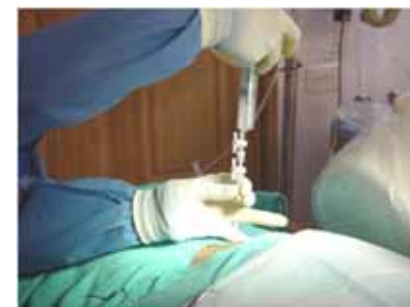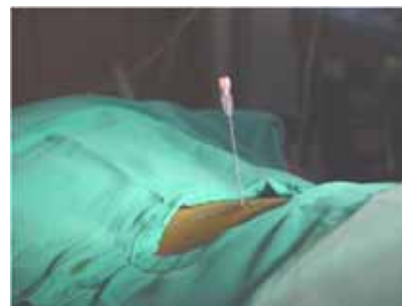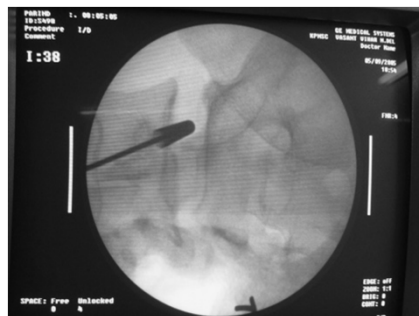
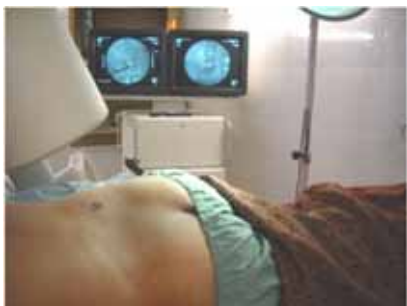Discogenic Pain




DISCOGRAPHY



Management; Discogenic pain - Intradiscal Ozone



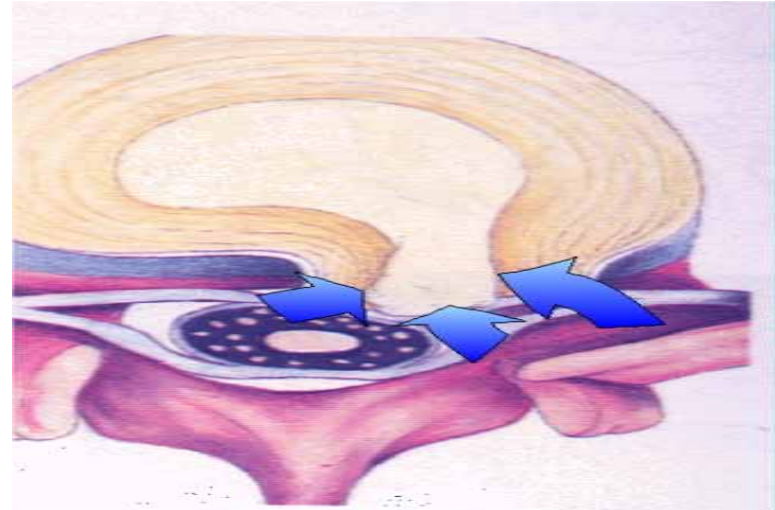


Direct Effect of Ozone

The gaseous mixture enters then in contact with the deformed discal surface that has altered intermolecular bonds.

These bonds are broken by the ozone molecule.

At two weeks, ozone stimulates new blood vessel formation in the disc (normally avascular in the adult) and eventually stimulates fibrosis and shrinkage of disc



Effect Of Ozone On The Cell-mediated Inflammatory Response

Indirect Effect of Ozone

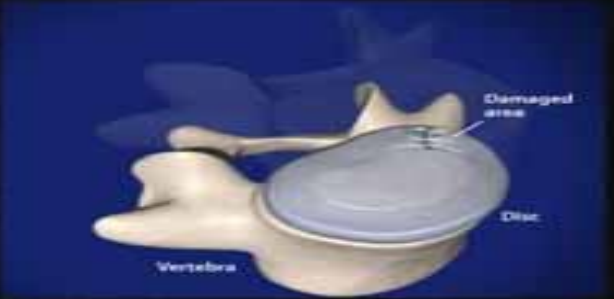

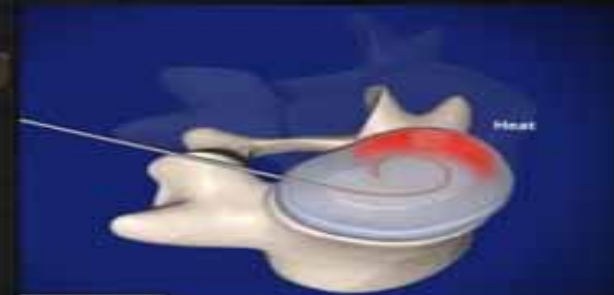

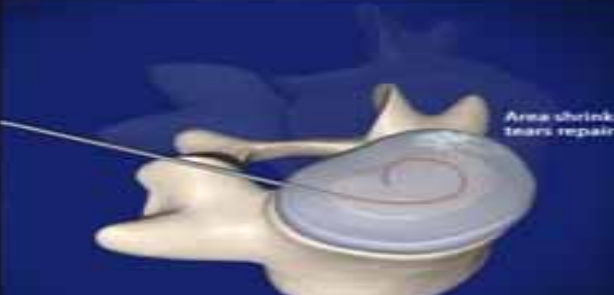

inhibiting the synthesis of pro-inflammatory prostaglandins

inhibiting the release of bradykinin or pain-inducing compounds

increasing the release of antagonists to the pro-inflammatory cytokines like interleukin 1, 2, 8 and 15

stimulating local production of anti-oxidant

Intradiscal Electrotherapy (IDET)

 <p>Vertebra Disc Damaged area</p>	<p>Temperature- 65 degree to 90 degree</p> <p>16 min</p>	 <p>B</p>
 <p>Heat</p>	<p>Nerve fiber damage</p>	 <p>F</p>
 <p>Area shrinks, tears repair</p>	<p>Stabilization of fissures</p>	 <p>B</p>

Discogenic Pain –Disc Biaculoplasty

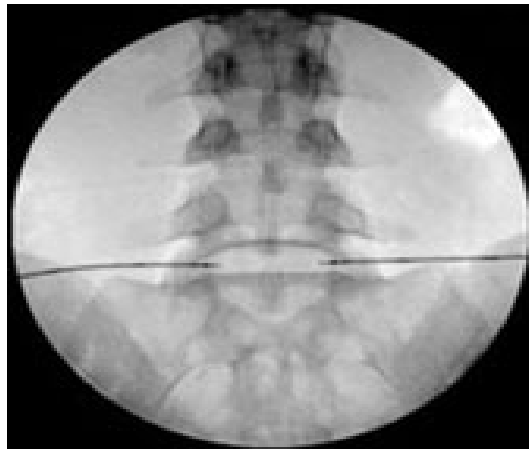
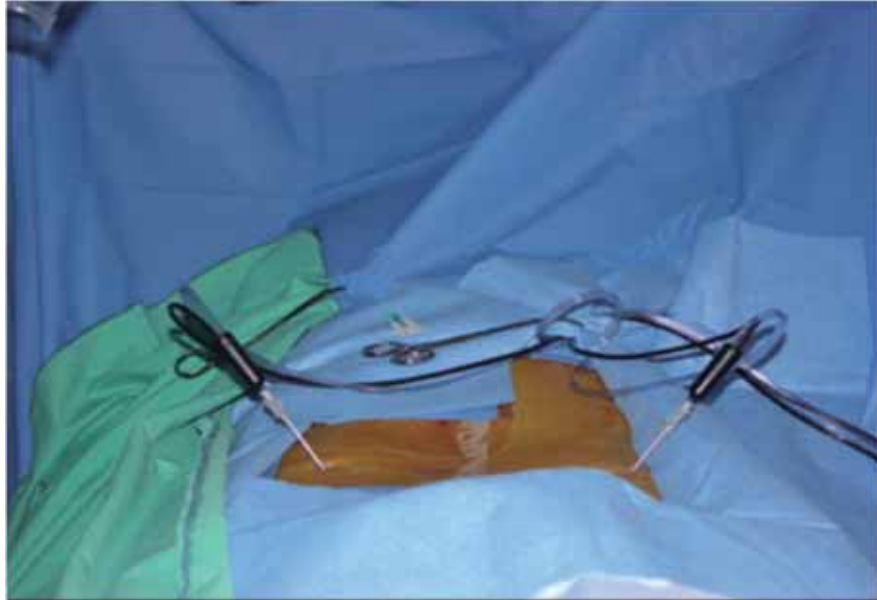
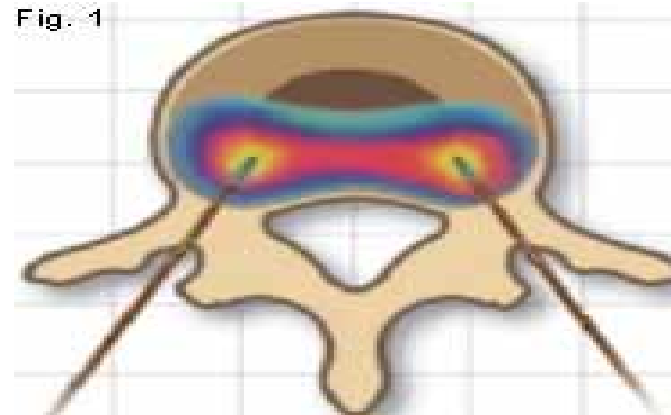
Fig. 1

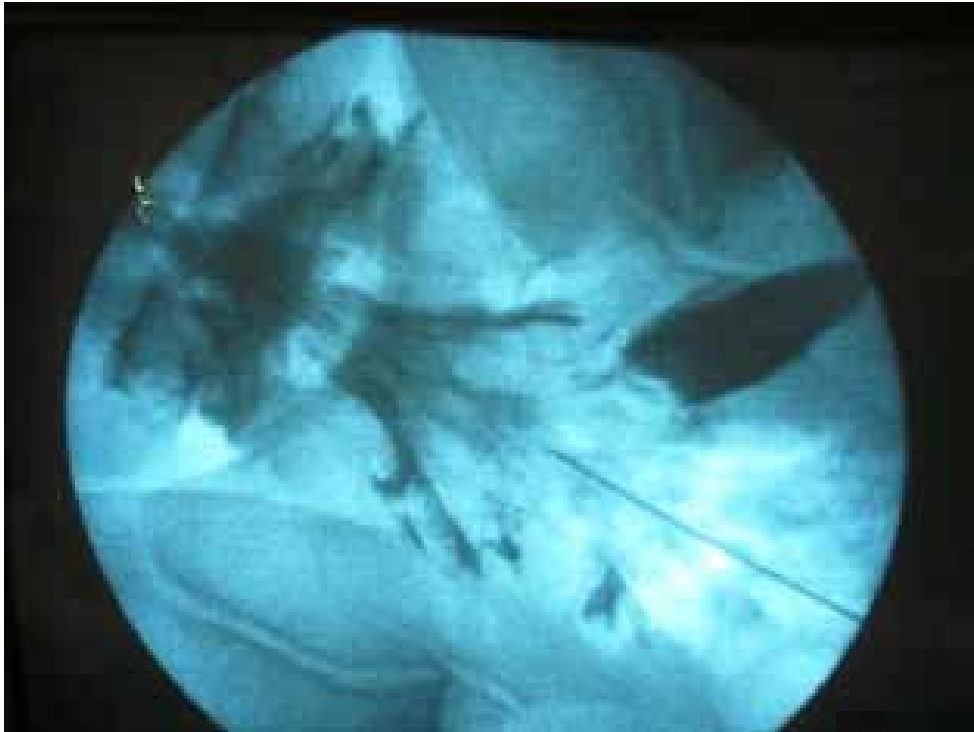


POST LAMINECTOMY SYNDROME (FBSS)

- Mechanical causes
 - Epidural fibrosis
 - Arachnoiditis
 - Psychosomatic pain
 - Systemic Medical Illness
-
- NOT AMENABLE TO SURGICAL TREATMENT

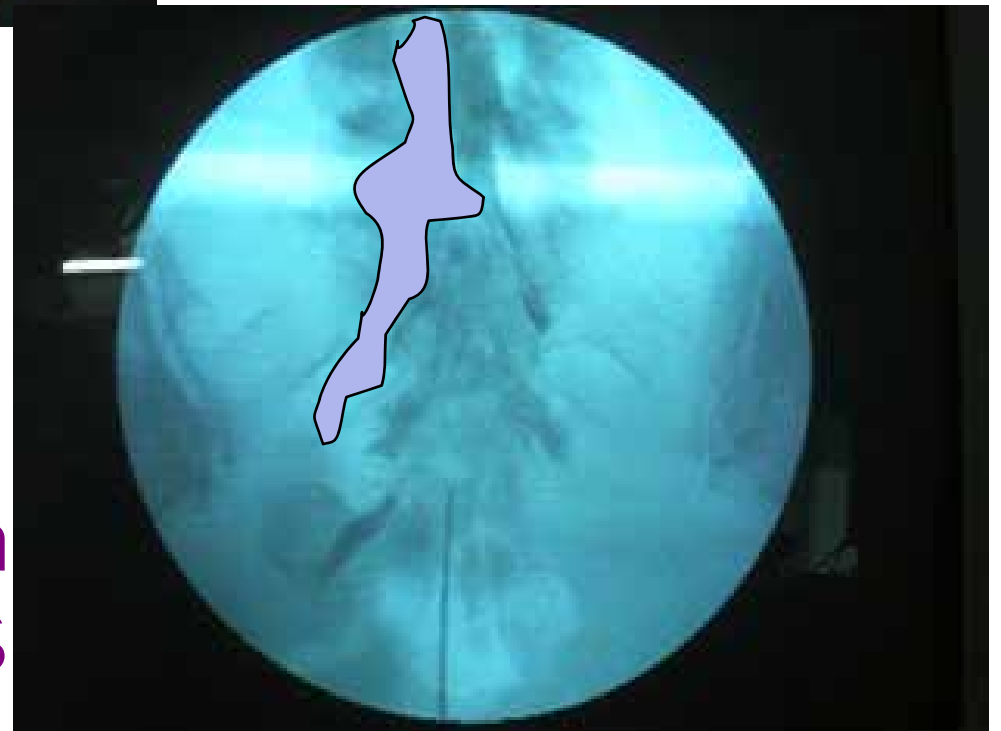
Epidurogram

- Normal Epidurogram looks like an inverted Christmas tree where dye enters into the dural extension of each nerve root.
- Filling defect in epidural spread of dye indicate Epidural fibrosis.



Epidurogram

Normal

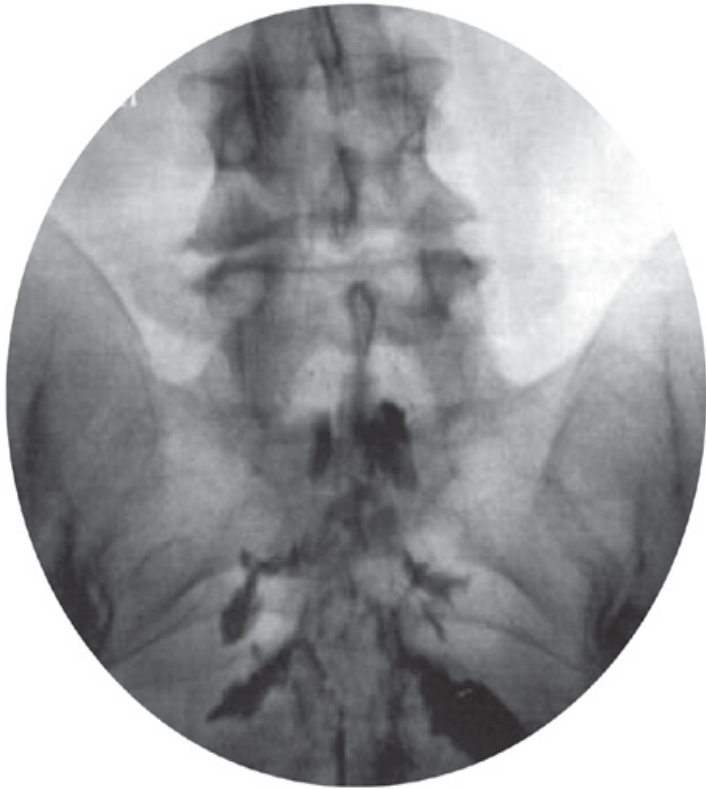

Filling defect in
FBSS

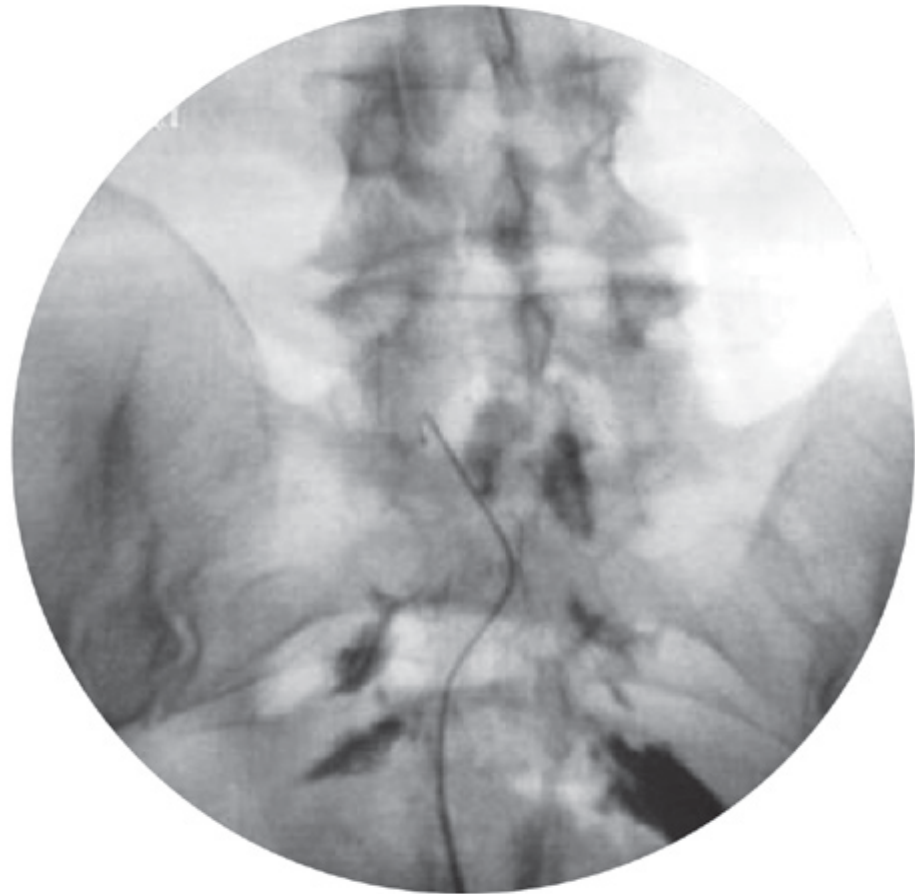
Epidurolysis

- Epidurolysis/ epidural adhesiolysis/ neuroplasty is done in epidural fibrosis with normal saline/hypertonic saline with/without hyaluronidase.
- It may be done with Racz catheter after performing an Epidurogram.

Epidurolysis



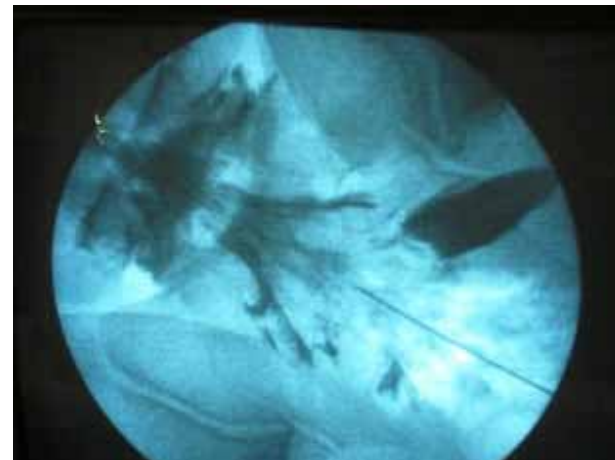
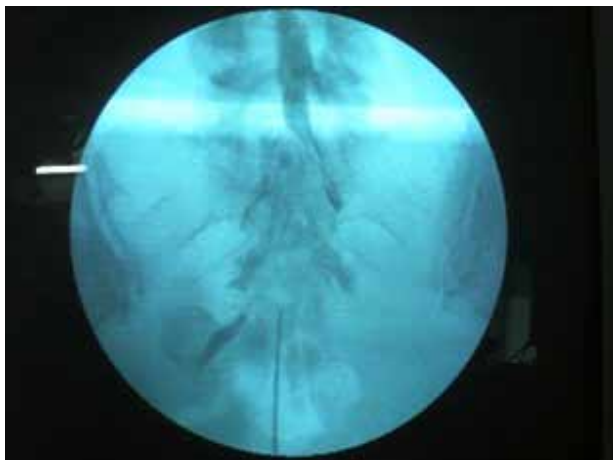
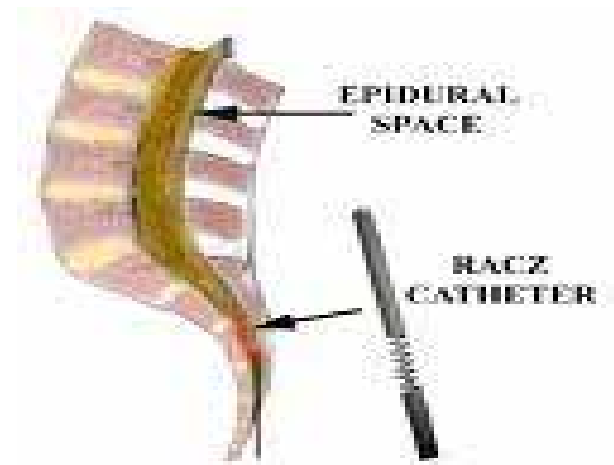
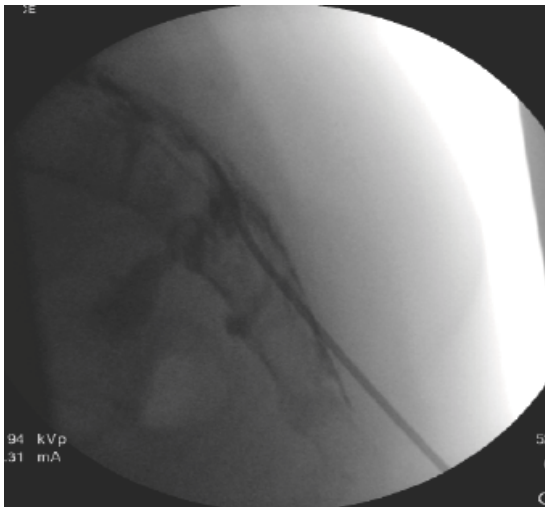
Epidurogram AP view with filling defects.



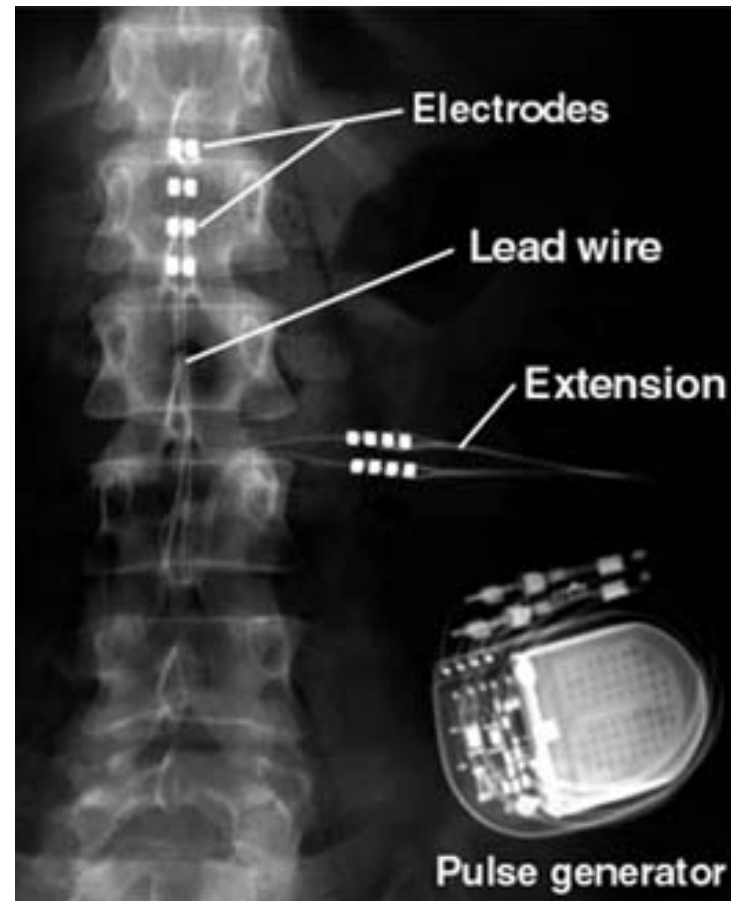
Racz catheter introduced and adhesiolysis carried out.

Failed Back Syndrome (FBSS)

- Epidural Adhesiolysis



Resistant Case of FBSS



Treatment of Pain

Operation

Recovery

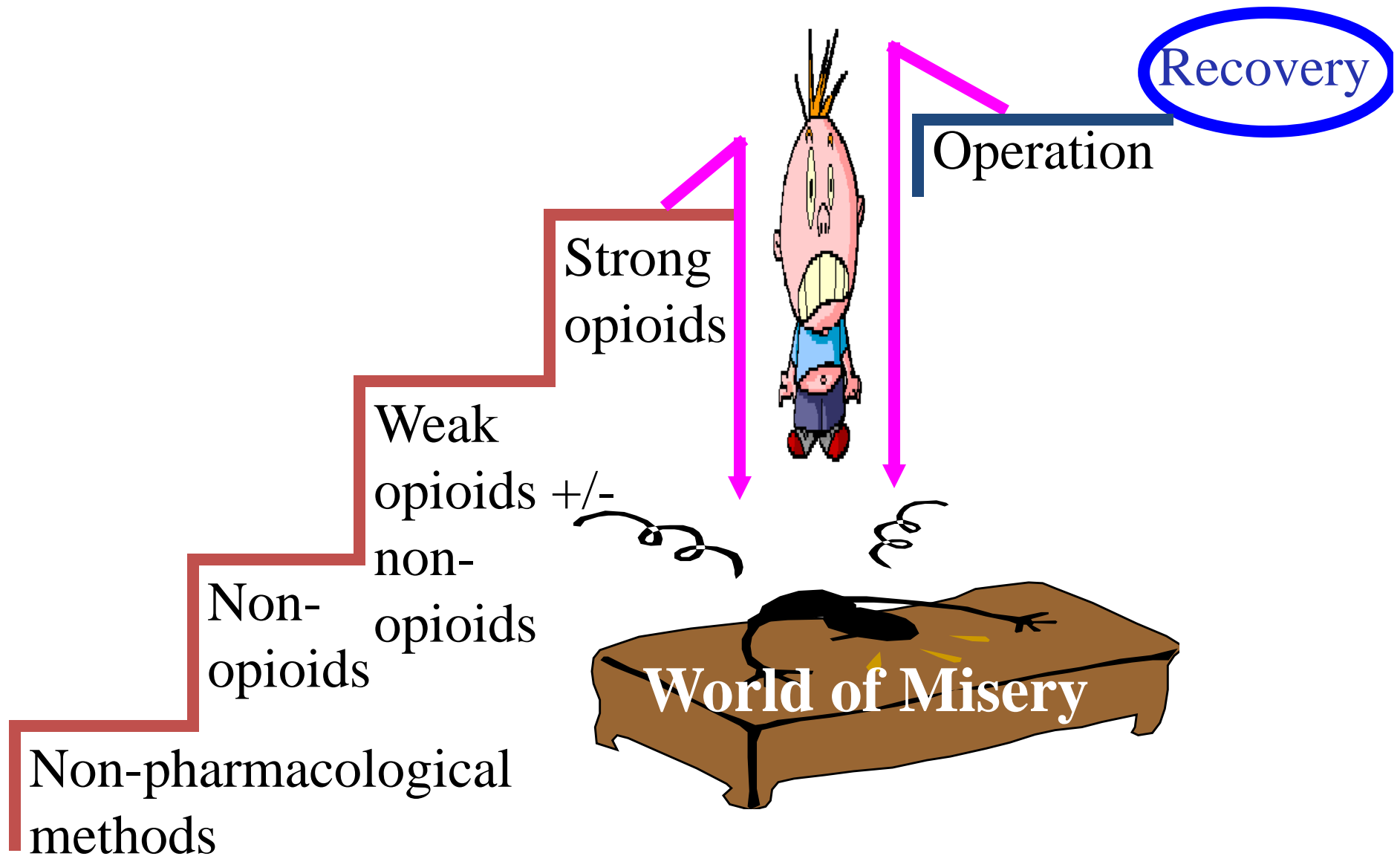
Strong
opioids

Weak
opioids +/-

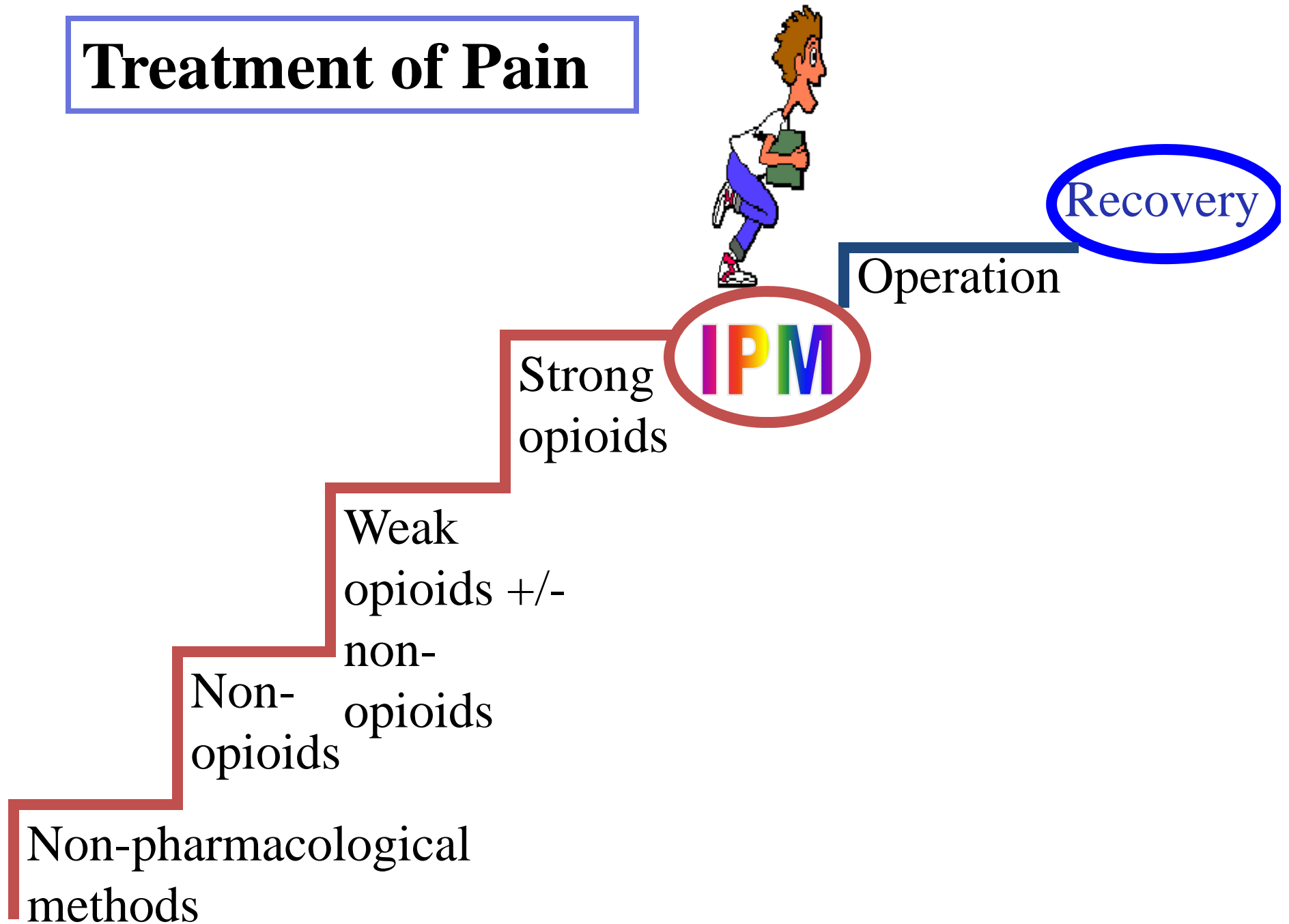
non-
opioids +/-
Non-
opioids
adjuvant

Non-pharmacological
methods

Treatment of Pain



Treatment of Pain



awareness

What do we need?

