

WHAT'S YOUR DIAGNOSIS?

2½ YEAR OLD GIRL PEDESTRIAN  
KNOCKED DOWN BY CAR WHILE  
CROSSING THE ROAD.

UNCONSCIOUS, IRRITABLE.

LACERATION ON FOREHEAD.

RESUSCITATED IN E.R.

INTUBATED.

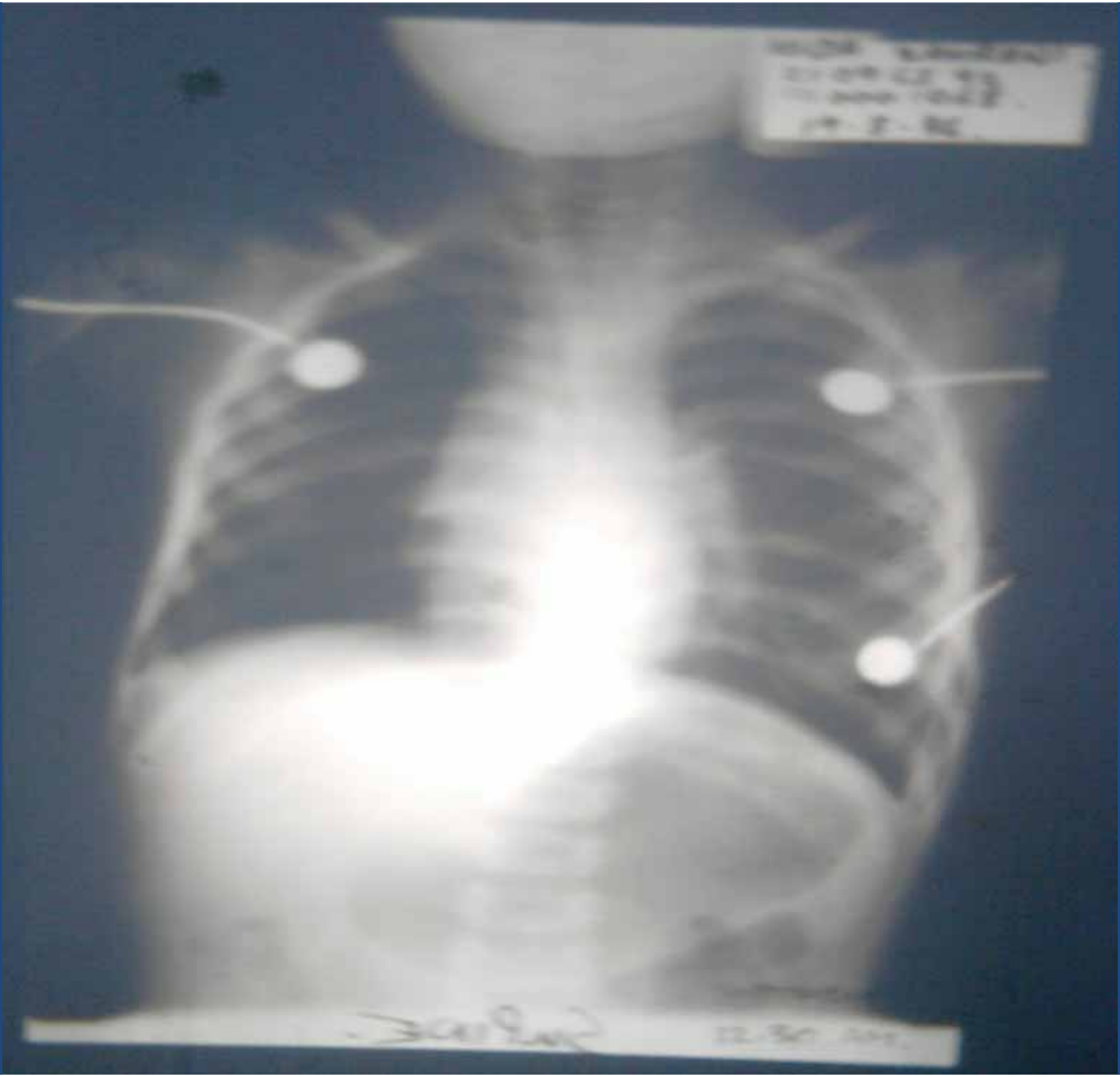
## XRAYS

SXR: NAD

CXR: (AP & LAT)

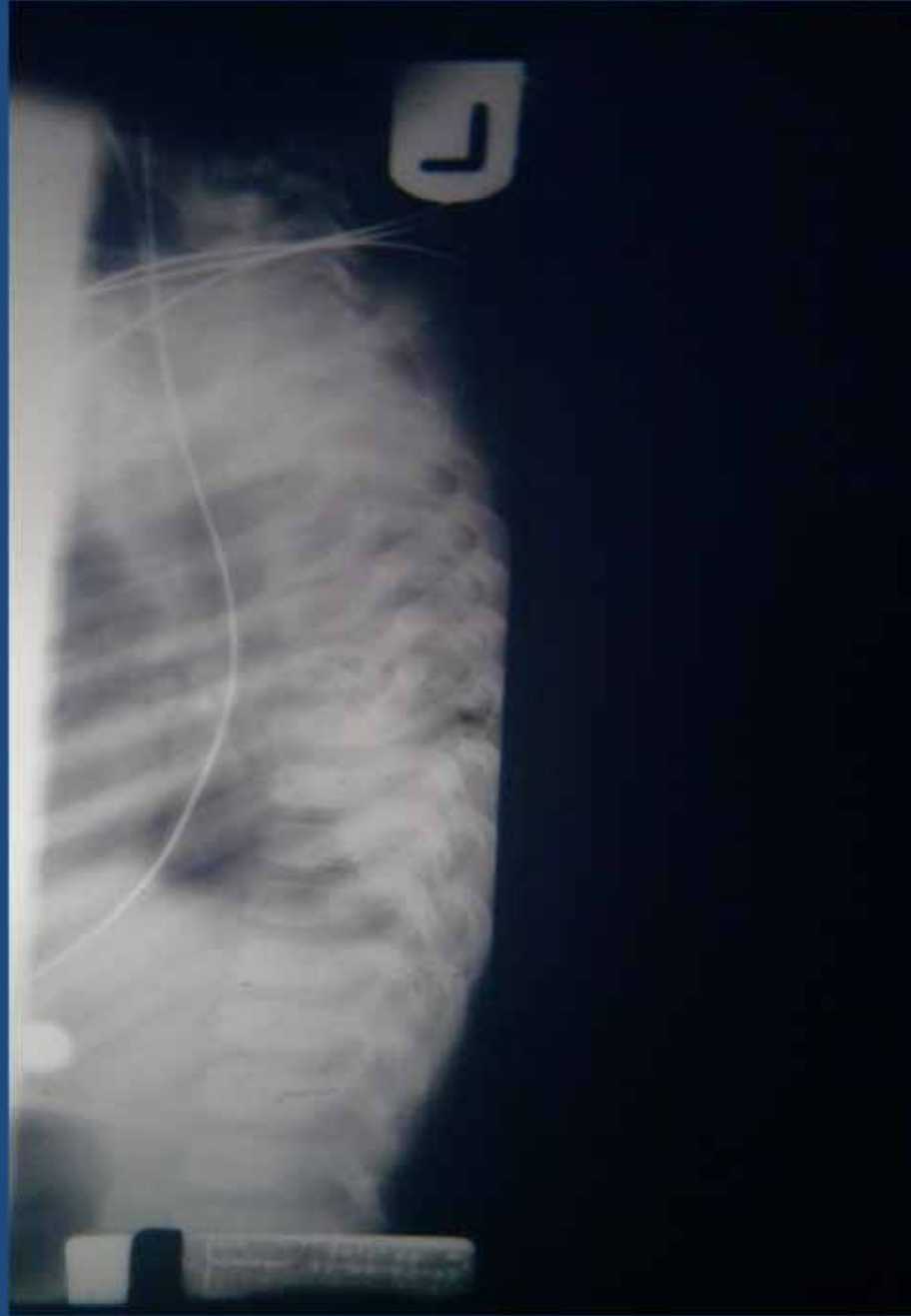FRACTURE DISLOCATION OF T<sub>8</sub>

NO HAEMOTHORAX OR PNEUMOTHORAX



WILSON, GARDNER  
11-29-53  
11-29-53  
11-29-53

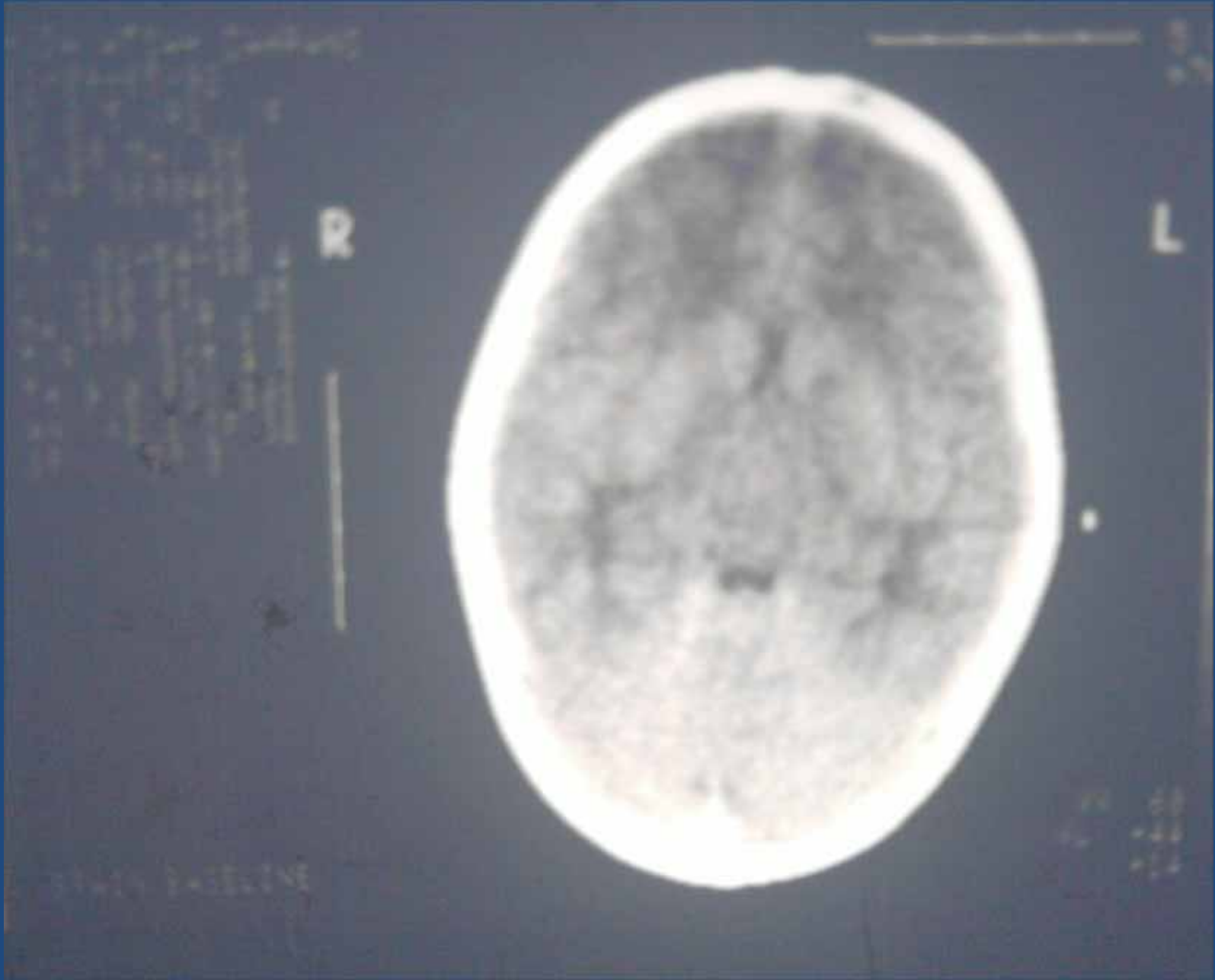
Wilson  
11-29-53



**C.T. SCAN (HEAD)**

**OBLITERATION OF VENTRICLES**

**BRAIN OEDEMA**





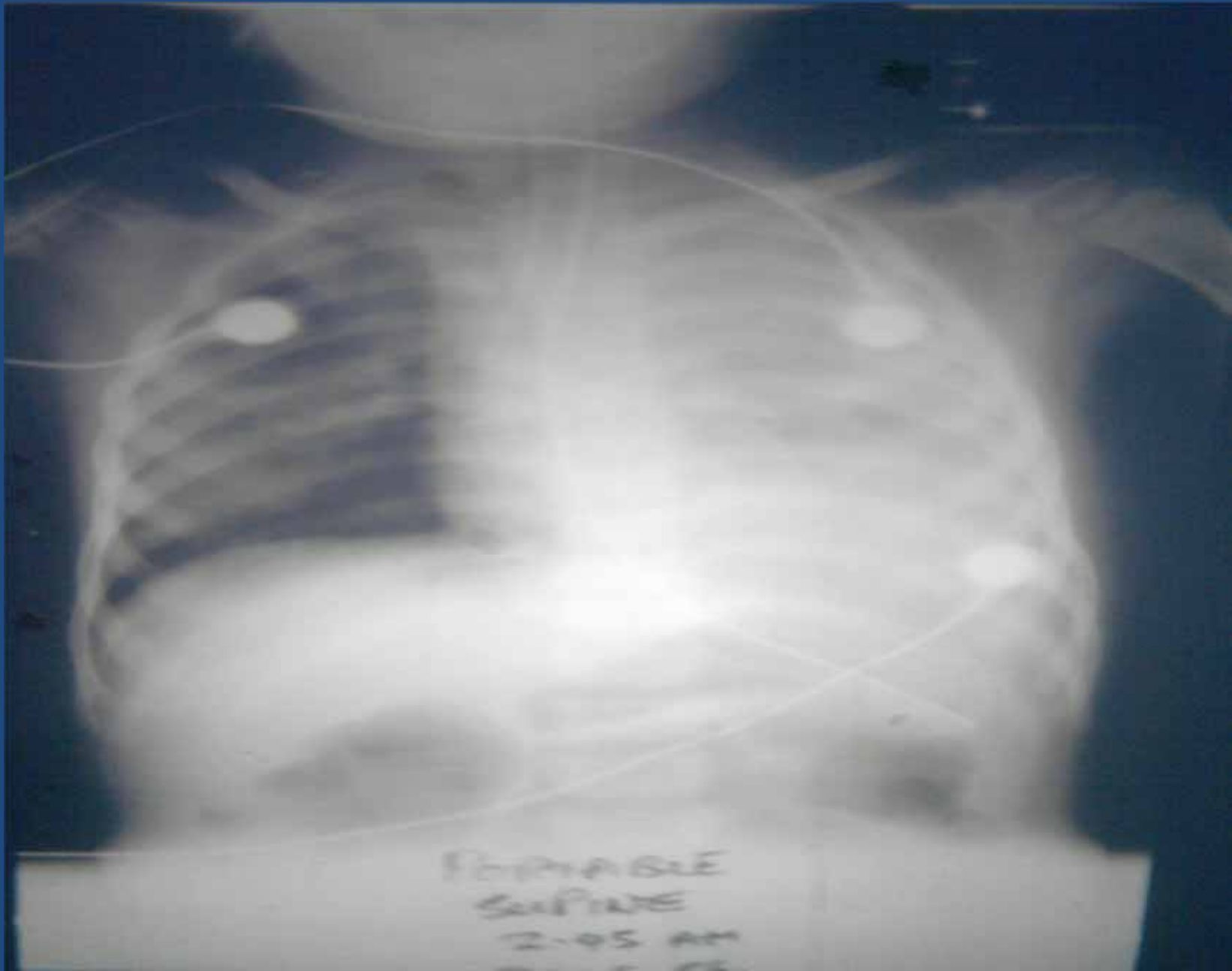

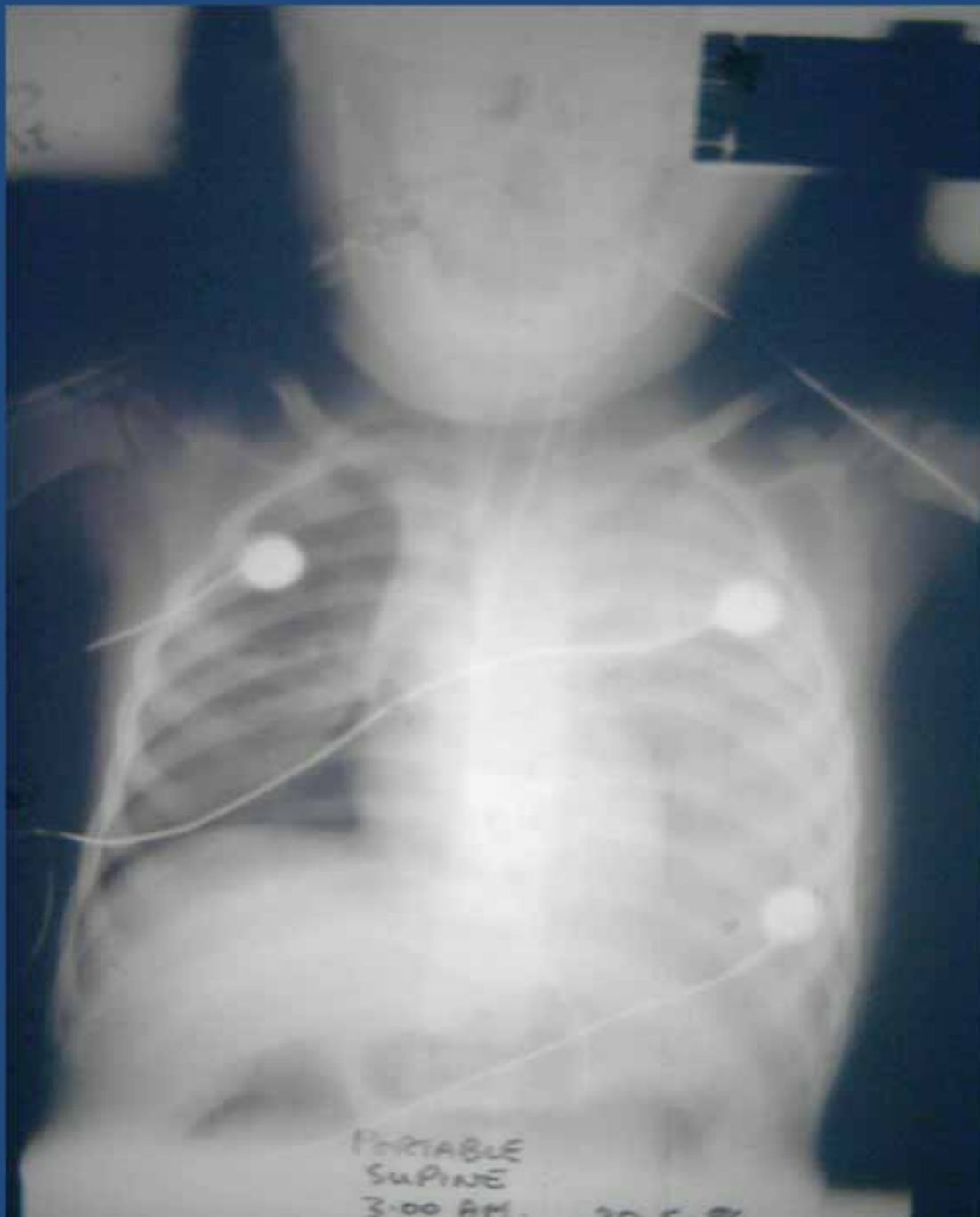
# MANAGEMENT

**ELECTIVE HYPERVENTILATION.**

**I.V. FLUID THERAPY**

**STEROIDS**





**HB DROPPED**

**11GM% TO 7.7GM%**

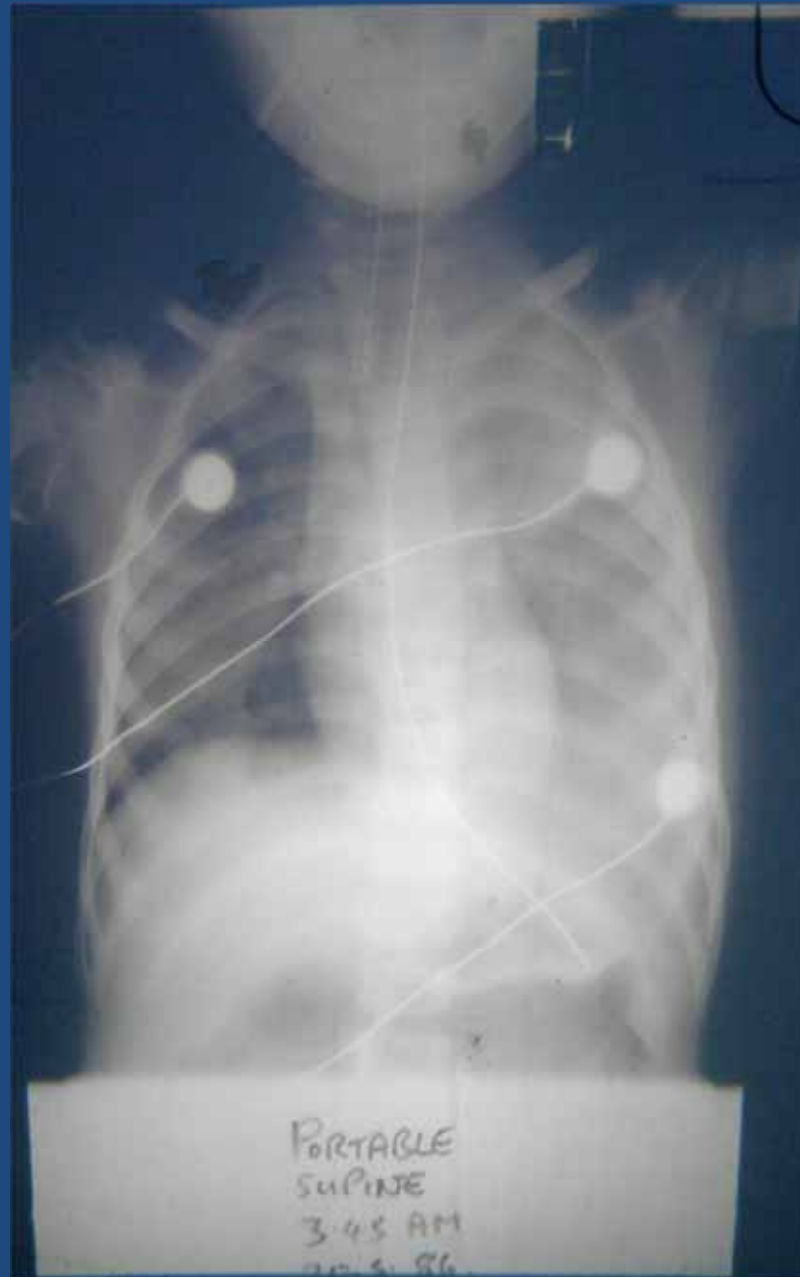
INCREASING OPACITY

+

DROP IN HB

=

HAEMOTHORAX



PORTABLE  
SUPINE  
3:45 AM  
10/5/86

CHEST DRAIN INSERTED  
AND INITIALLY 400 ML  
OF BLOOD DRAINED.



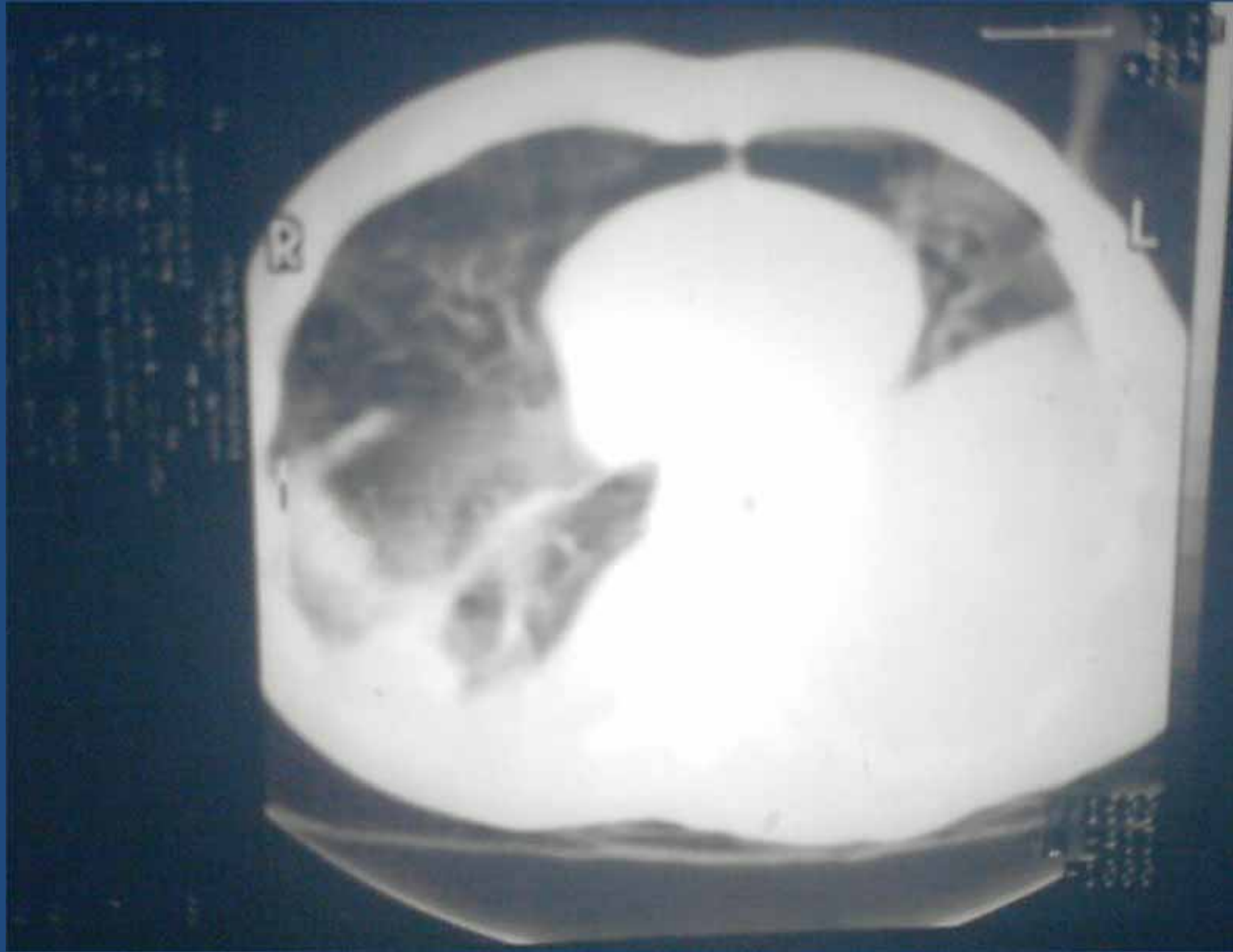

THE FOLLOWING DAY PATIENT  
MORE ALERT, OPENING EYES  
TO SPEECH.

MOVING UPPER LIMBS SPONT--  
ANEOUSLY. NO MOVEMENT IS  
NOTED IN LOWER LIMBS

**C.T. SCAN THORACIC SPINE**

**CONFIRMS FRACTURE T<sub>8</sub> VERTEBRA**



PRESENCE OF AIR IN SPINAL  
CANAL AND MEDIASTINUM -  
? OESOPHAGEAL RUPTURE.  
HOWEVER, METHYLENE BLUE  
INJECTED INTO OESOPHAGUS  
FAILED TO APPEAR IN CHEST  
DRAIN.

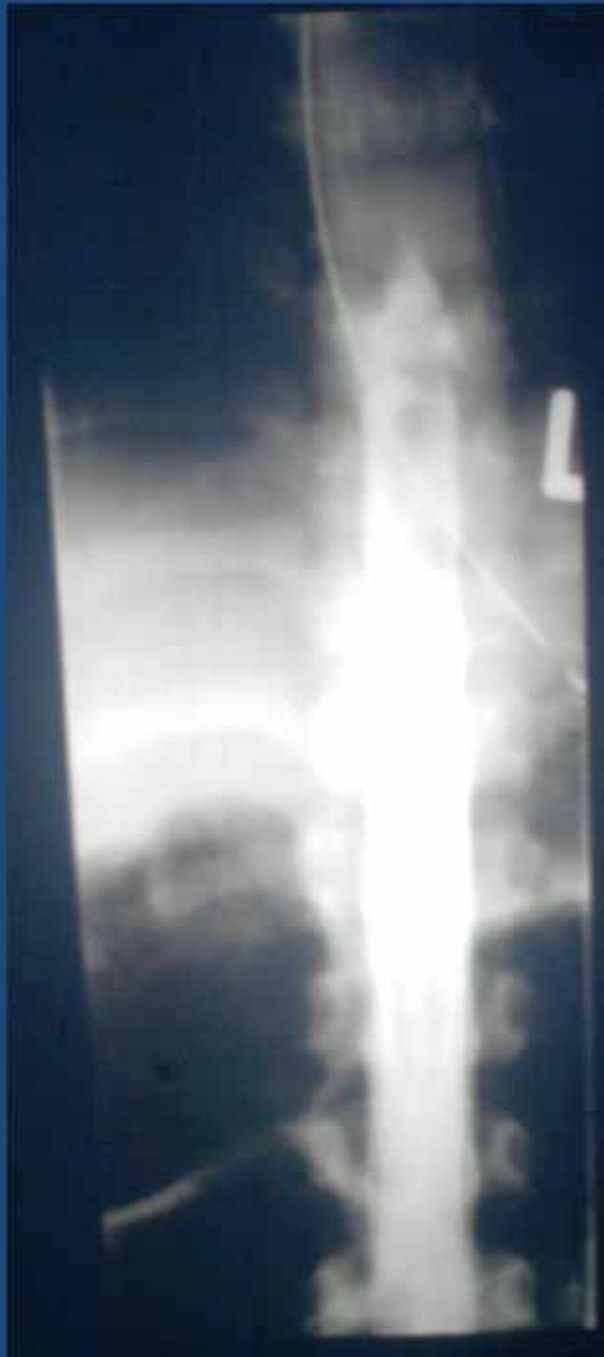## PLEURAL DRAINAGE:

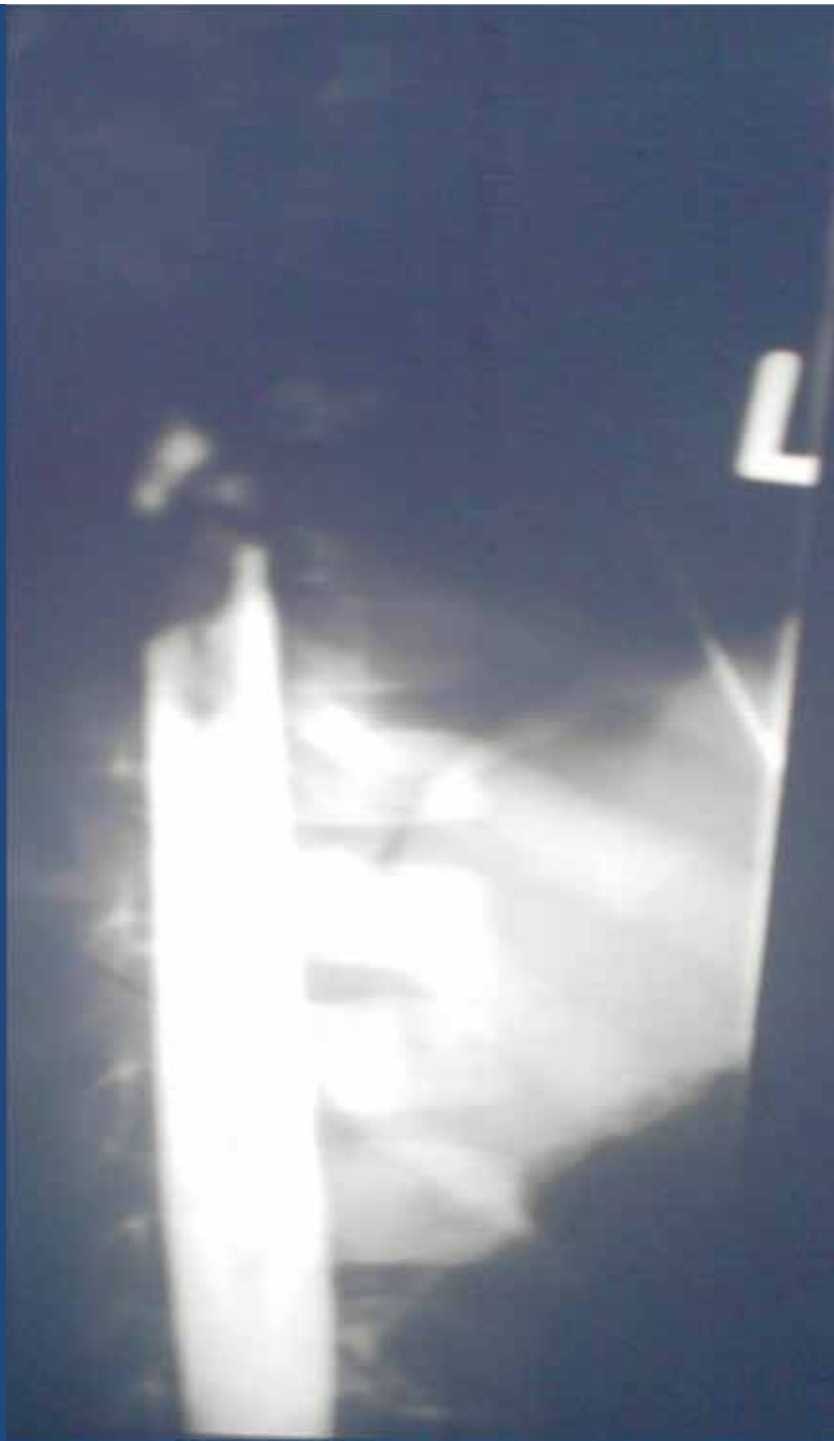- (I) BECOMING CLEARER
- (II) AMOUNT RANGING  
225 - 305 ML/DAY

**POSSIBILITY OF CSF LEAK  
THROUGH CHEST DRAINAGE**

**CHEMICAL ANALYSIS OF FLUID  
DRAINING CONFIRMS CSF.**







OPERATION AIM:

ATTEMPT AT REPAIR OF CSF  
FISTULA VIA LAMINECTOMY.

## FINDINGS:

DISLOCATION OF T<sub>8</sub> VERTEBRA.

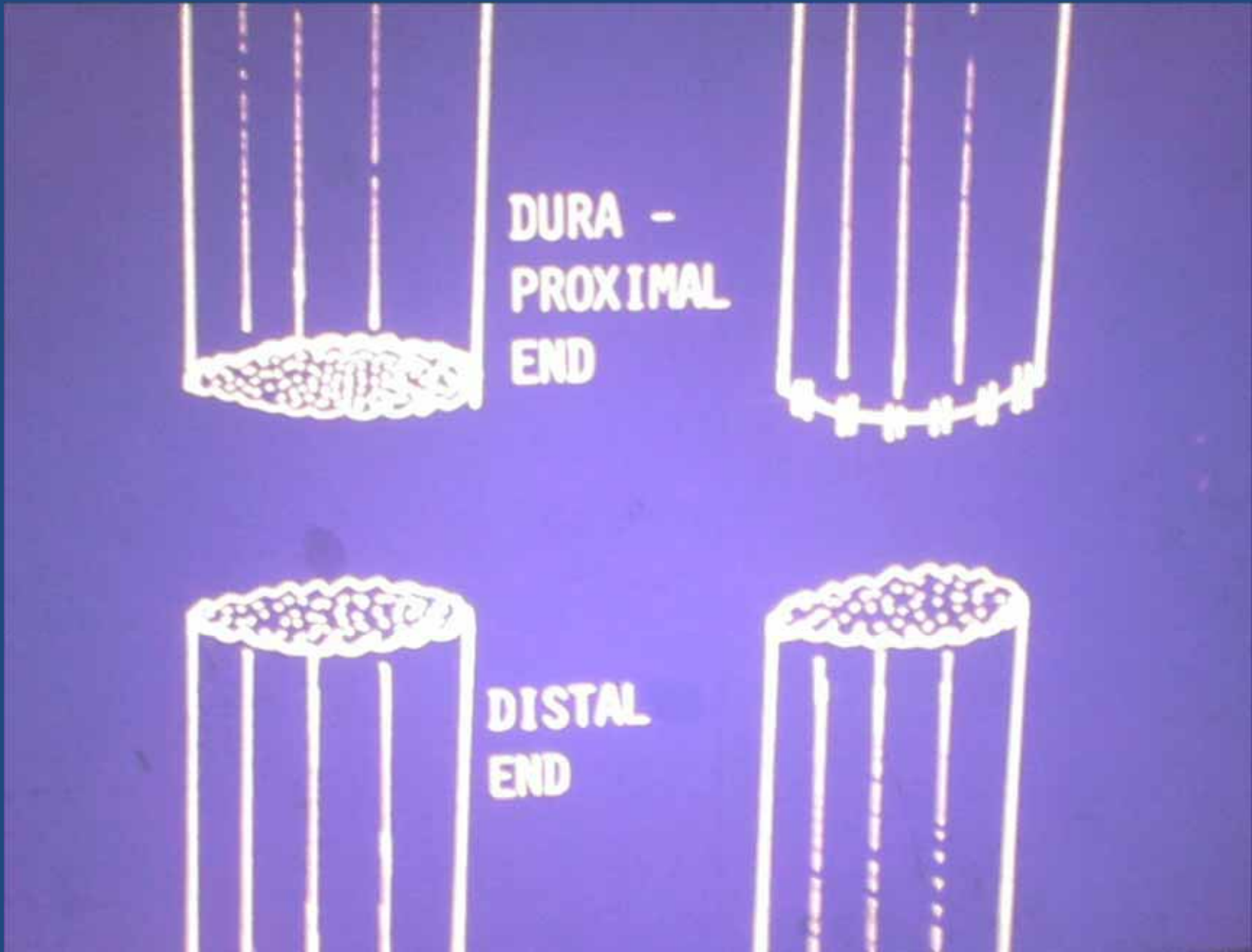COMPLETE RUPTURE OF DURA.

LIQUEFACTION NECROSIS OF SPINAL

CORD OVER A LENGTH OF 2.5 CM.

## PROCEDURE:

WATER TIGHT CLOSURE OF THE  
PROXIMAL END OF THE DURA AS A  
CUL-DE-SAC.



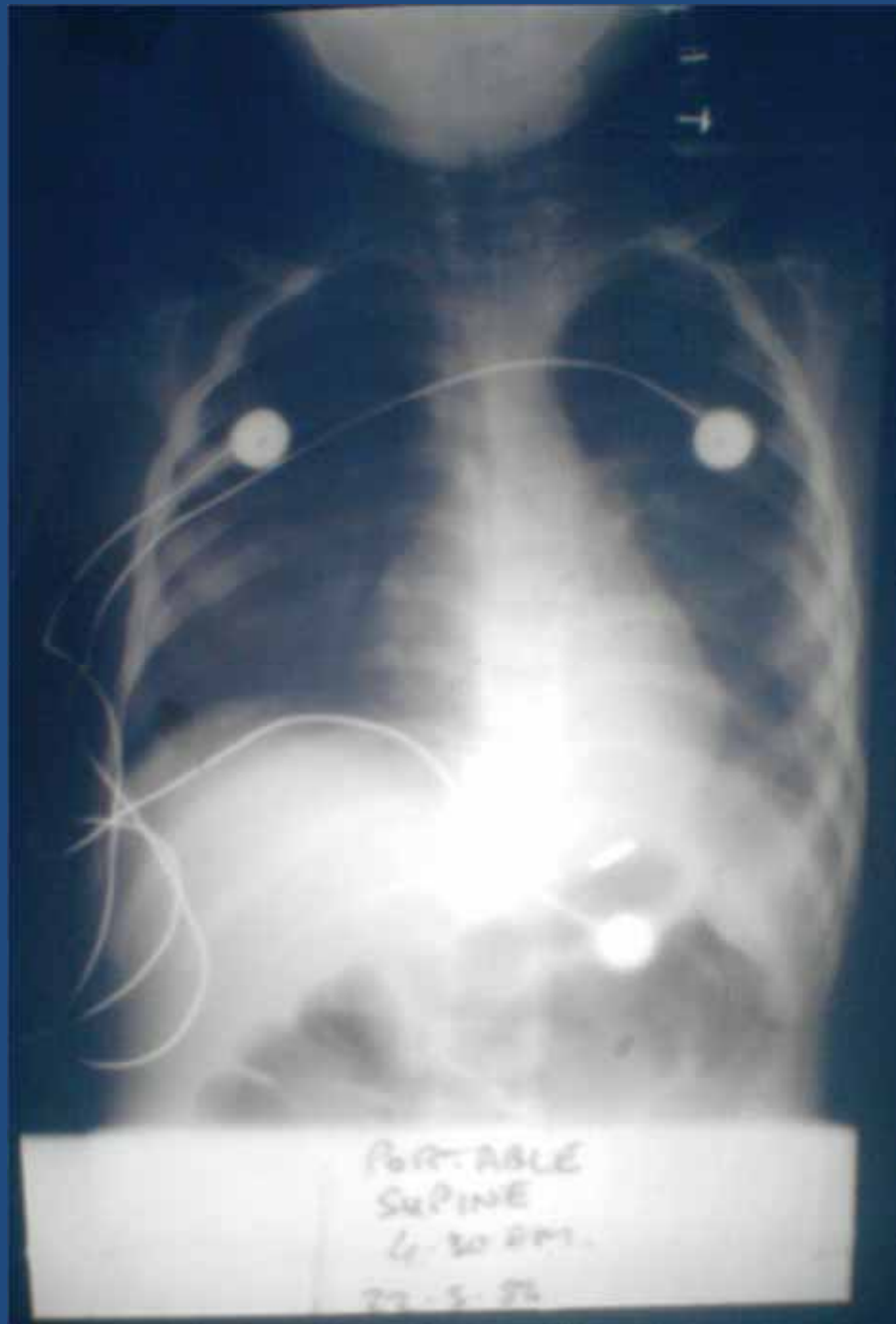## POST-OPERATIVE

UNEVENTFUL RECOVERY.

FULLY ALERT CONSCIOUS.

CHEST DRAIN REMOVED THE FOLLOWING  
DAY.

PATIENT PARAPLEGIC



PORTABLE  
SUPINE  
4-20 AM.  
77-5-75



# TRAUMATIC DURAL-PLEURAL FISTULA:

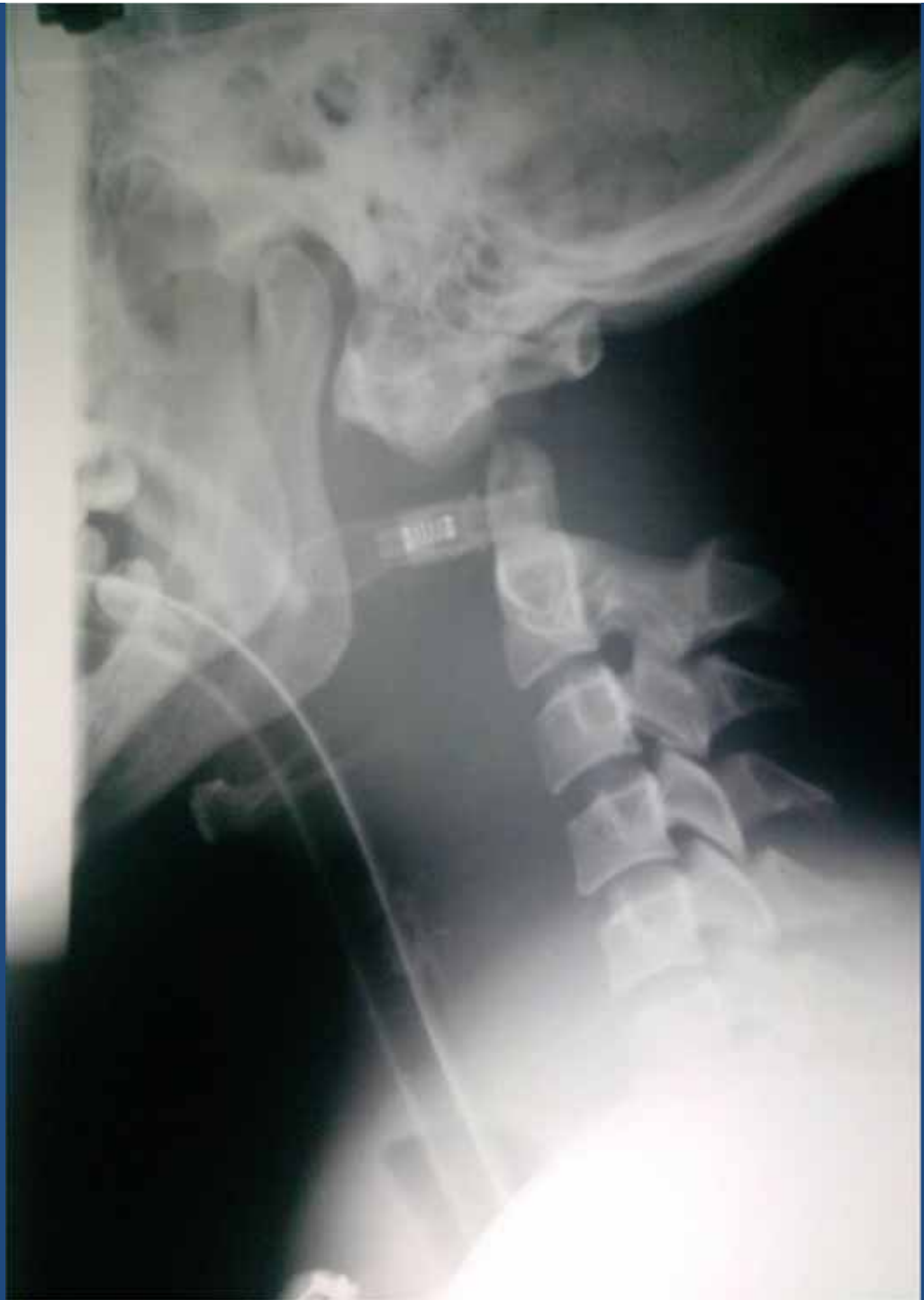## A CASE REPORT

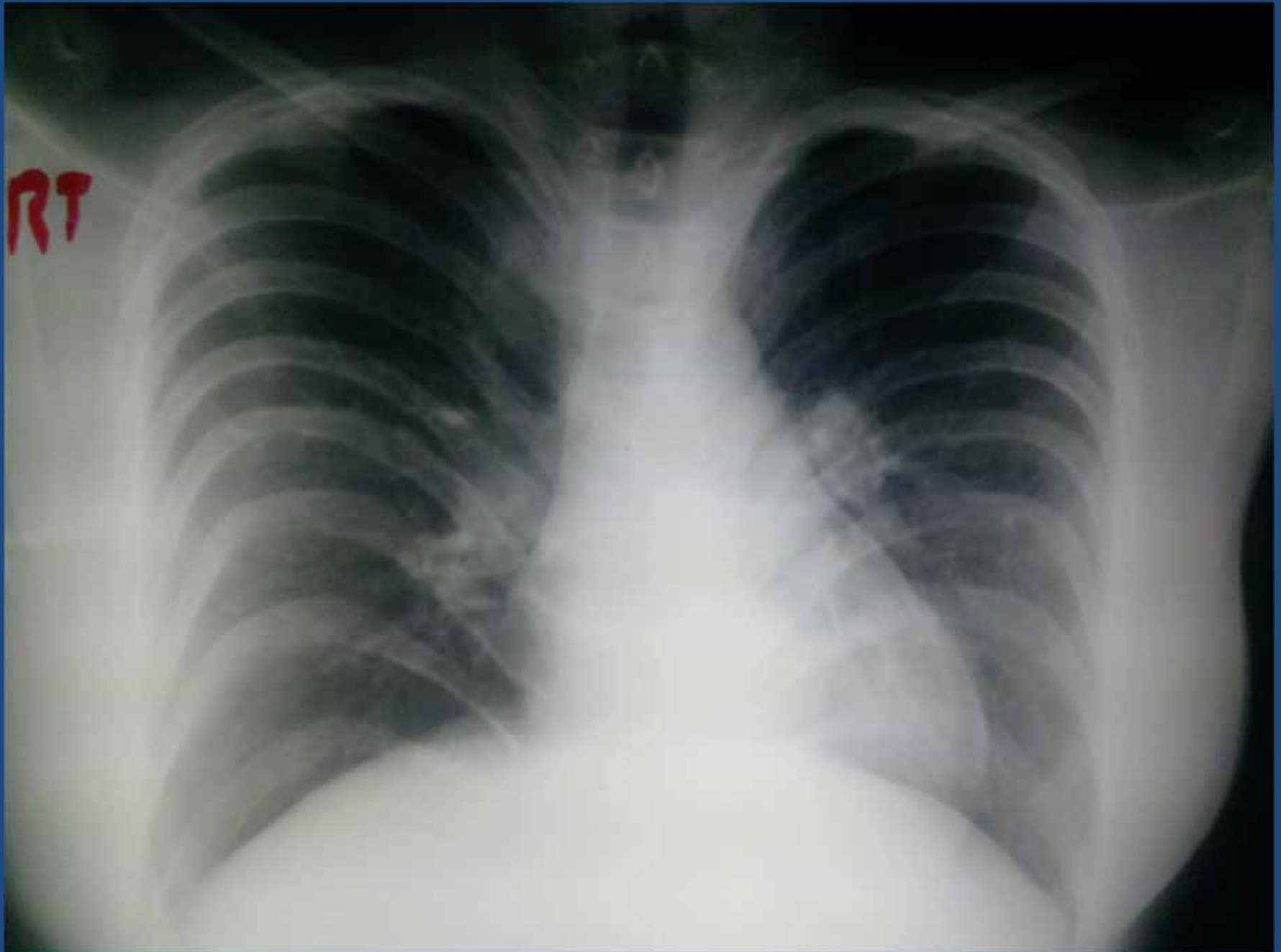
DR. RAMESH MODUN

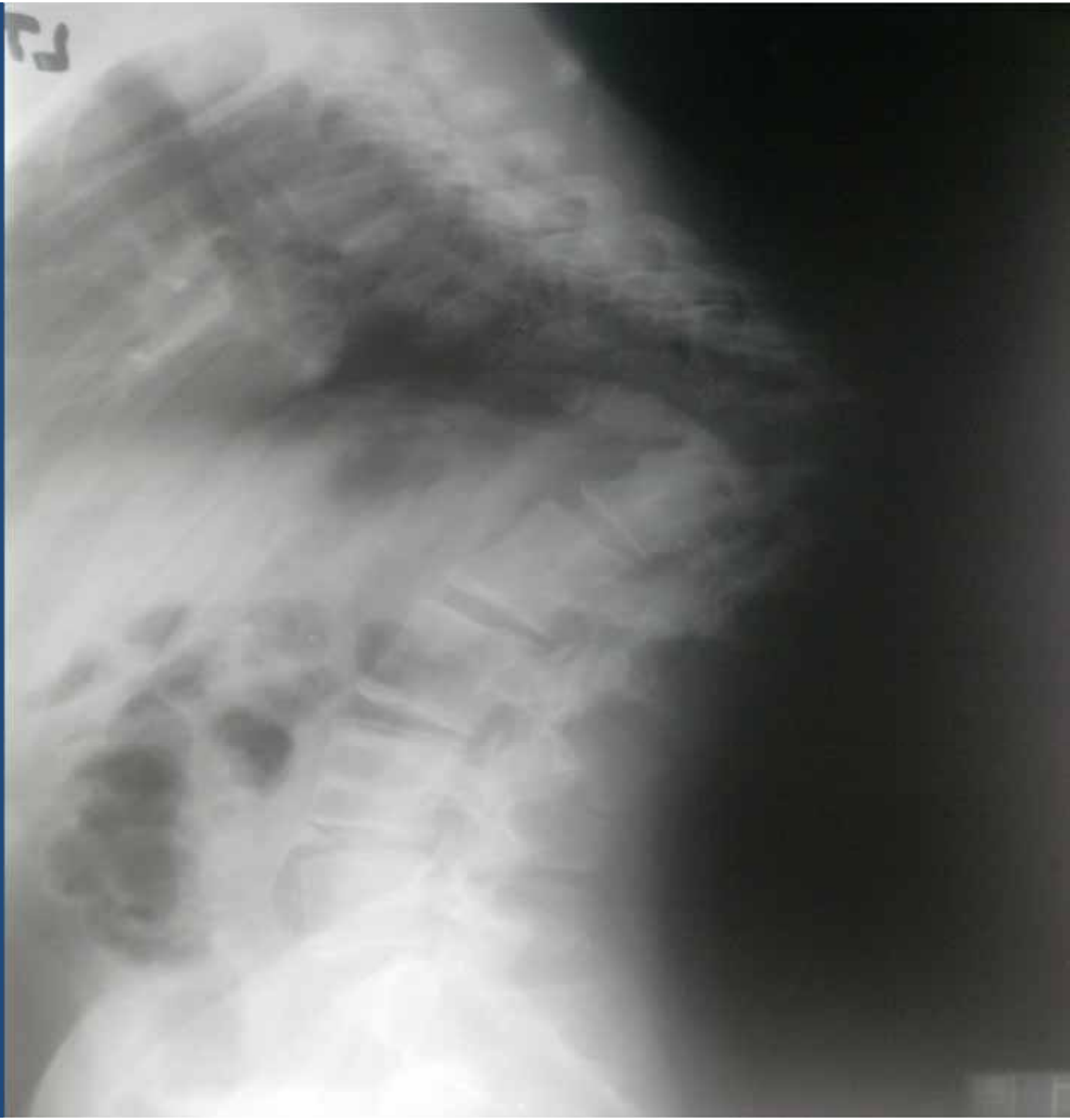DR. REIJO LUOMA

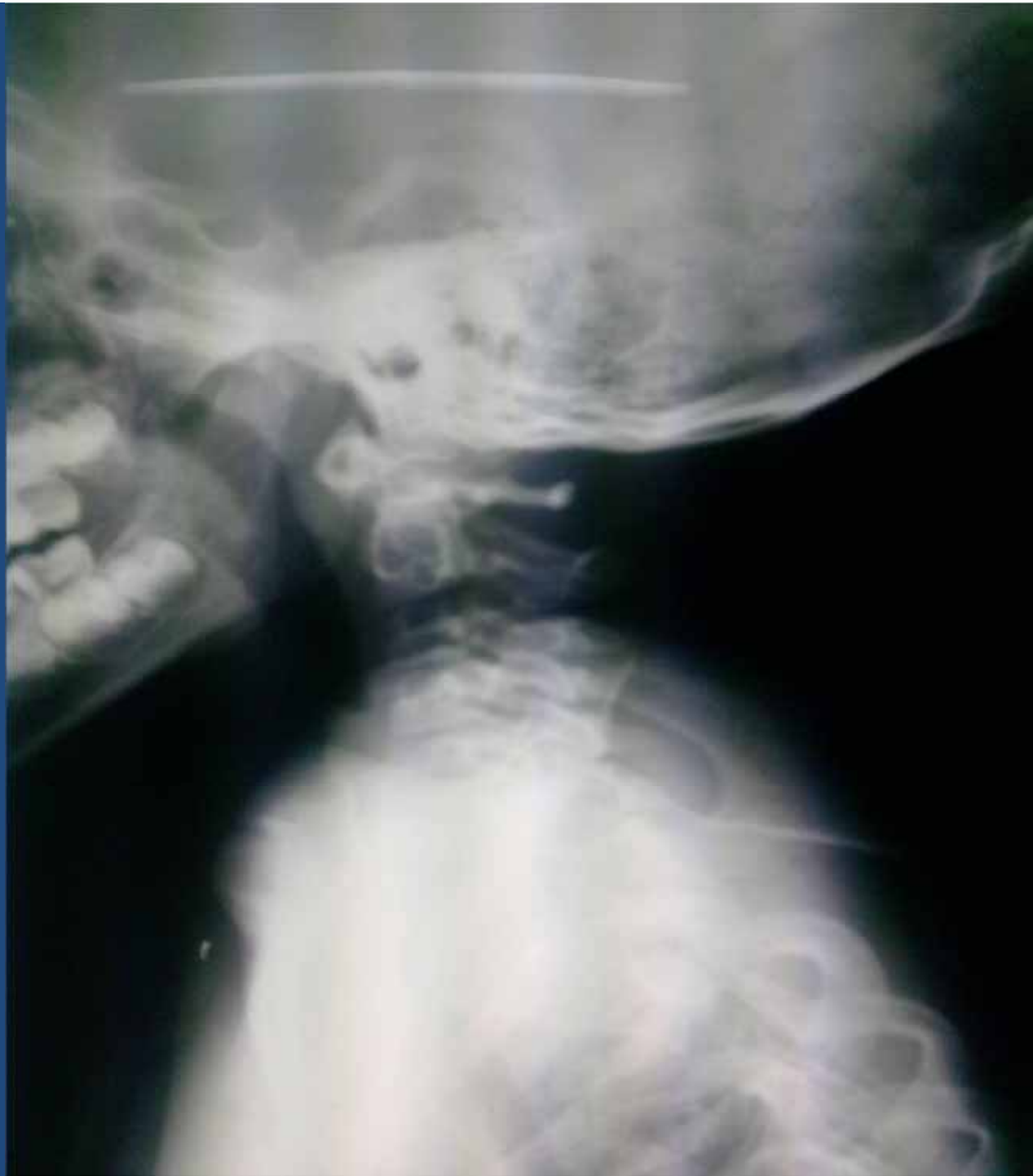KING FAHD MILITARY HOSPITAL, JEDDAH

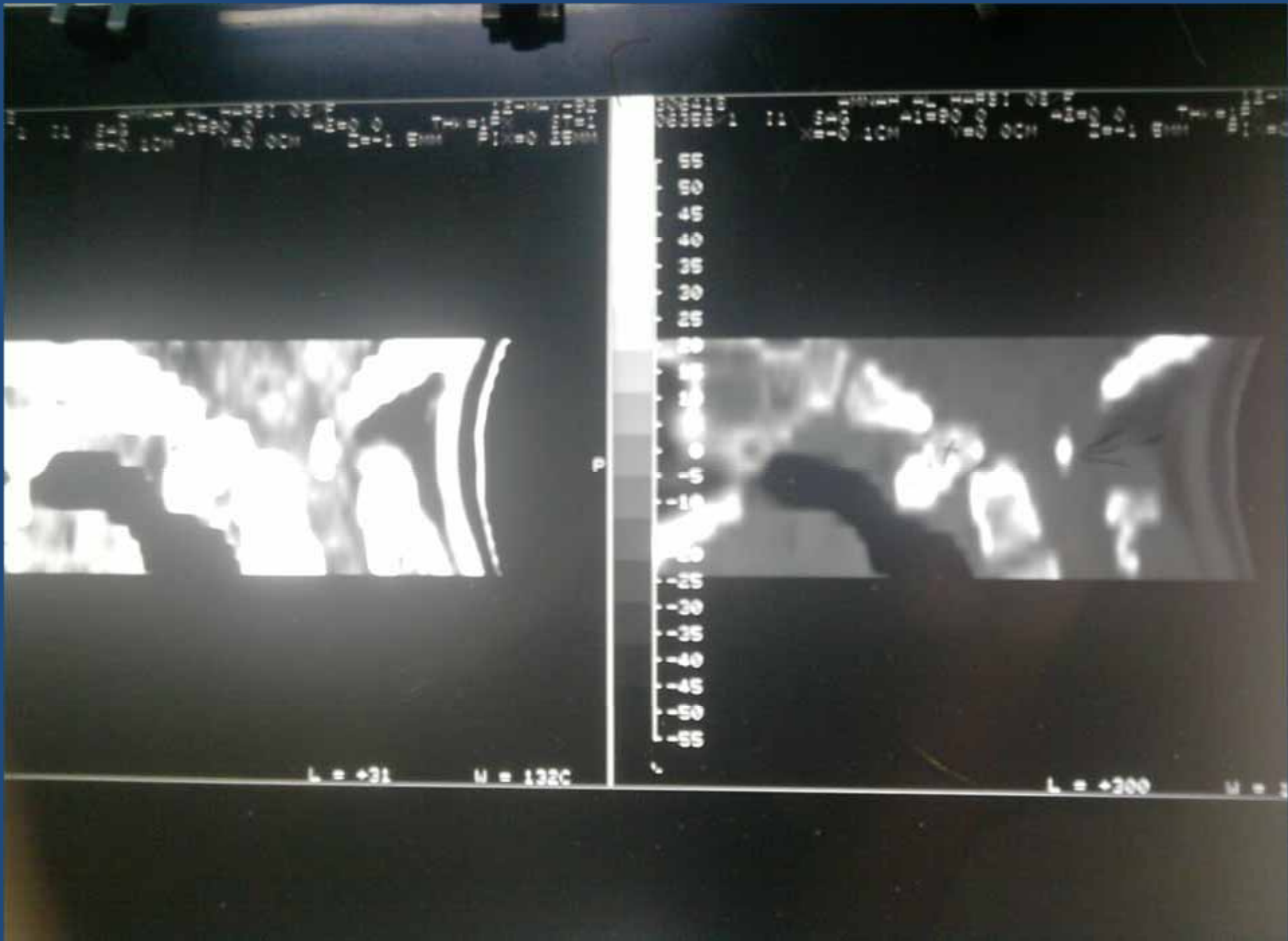# Medical Curiosities...

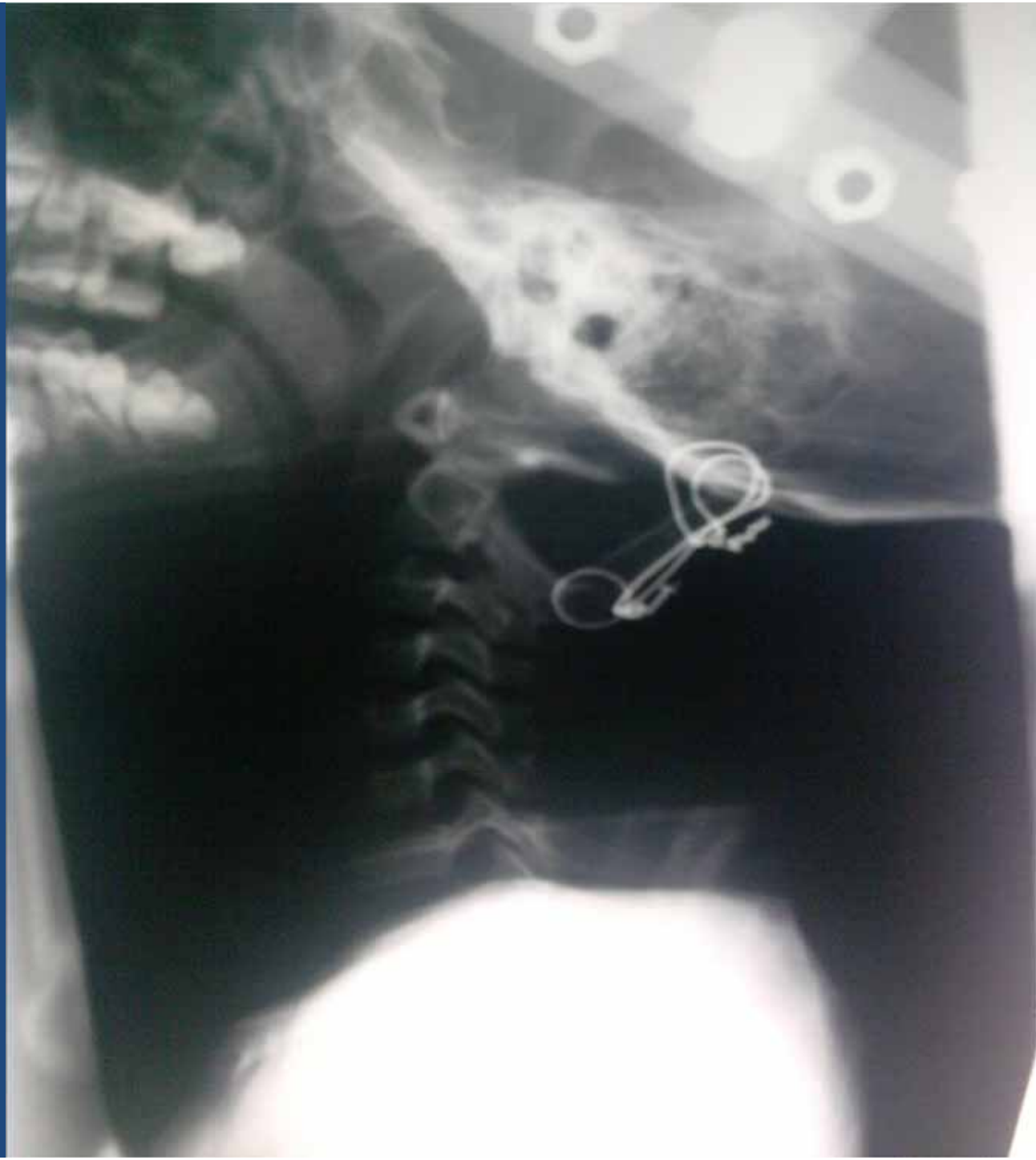




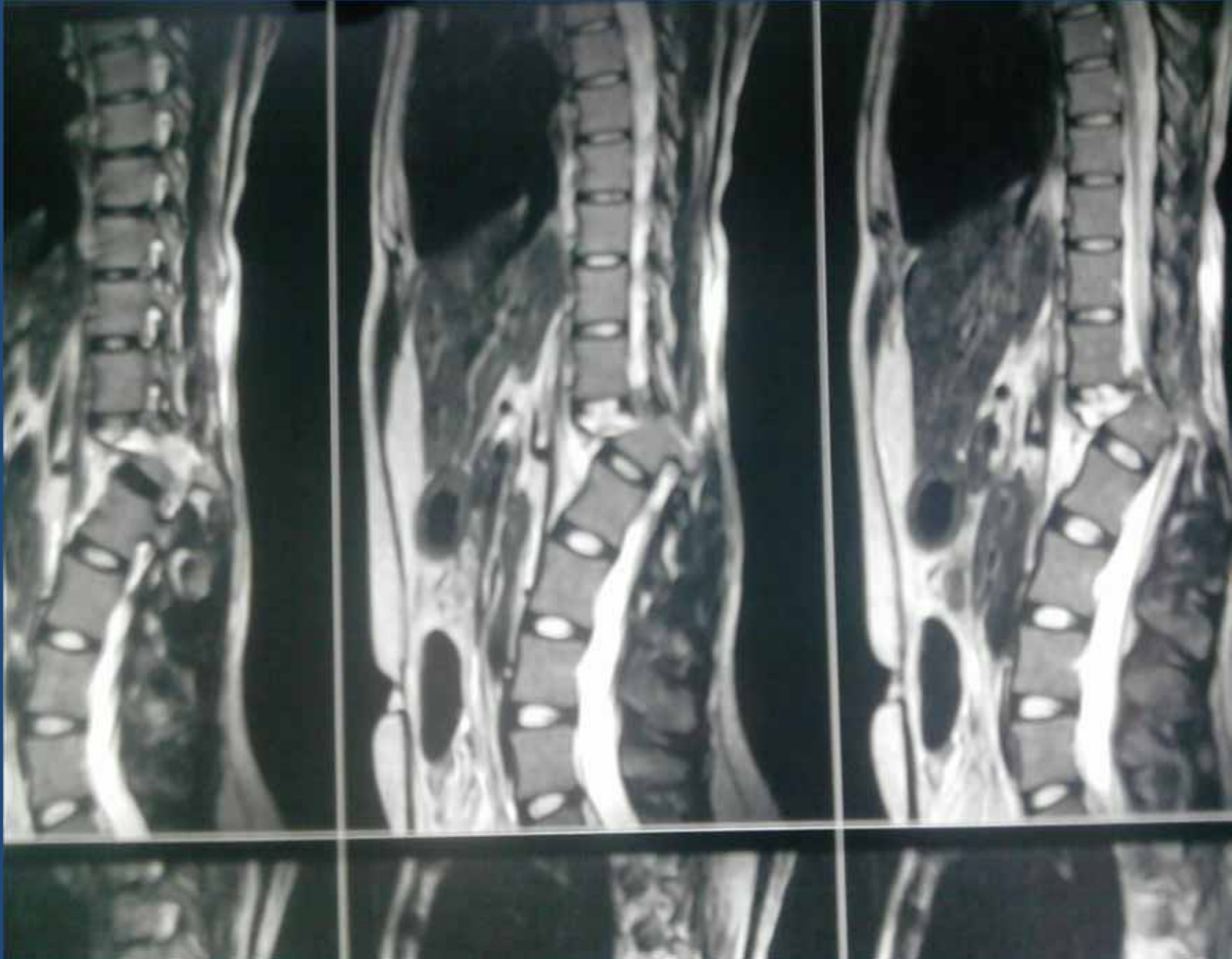










THANK YOU