

Concluding with Radiological Images

Dr Tejas Ghoorah
MBBS, MD Radiodiagnosis, MRCR UK

Date : 13.08.2014



Medical Excellence

Case 1

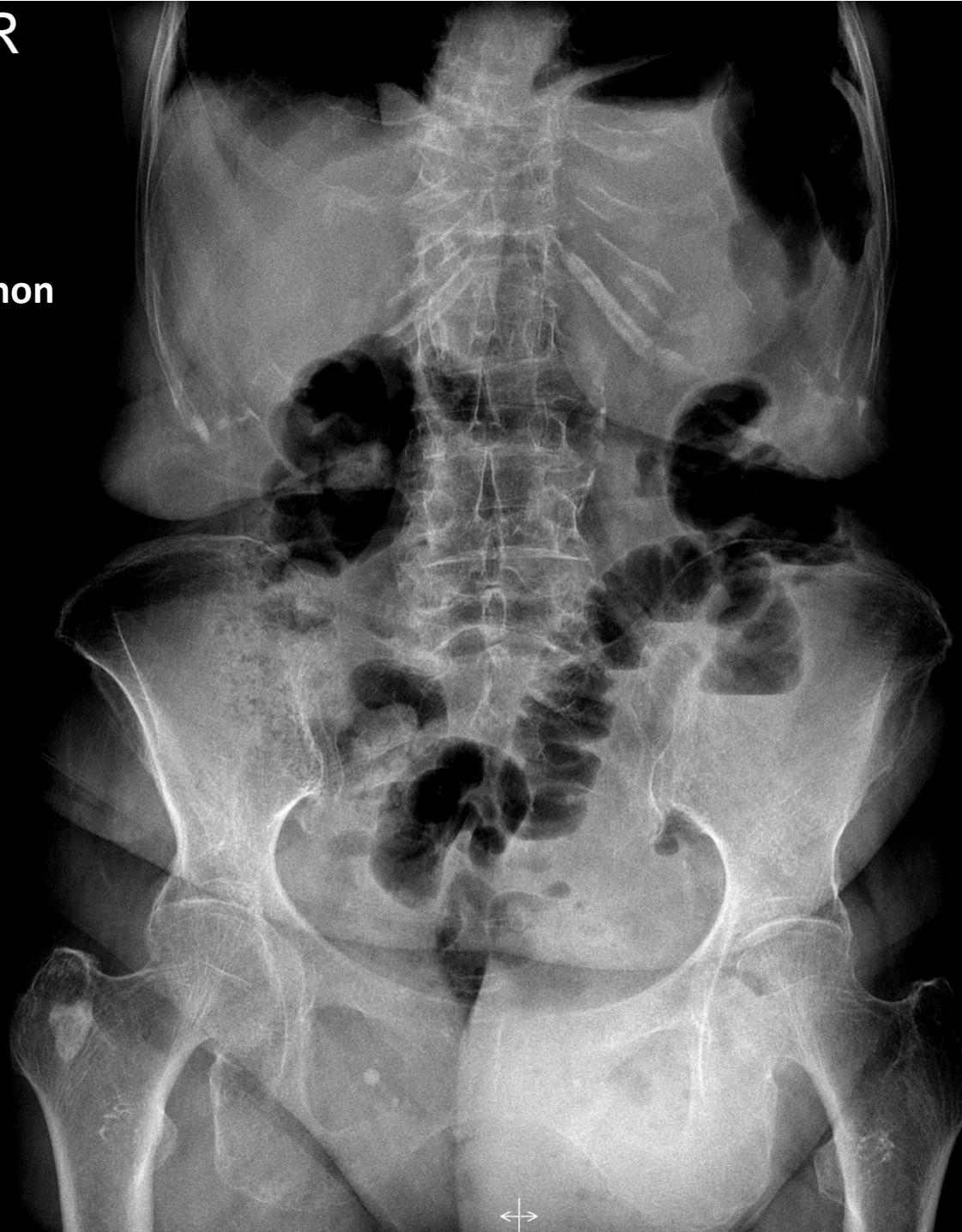
Slide Number : 1



Medical Excellence

R

83 years old lady
Vomiting with left non
reducible inguinal
hernia

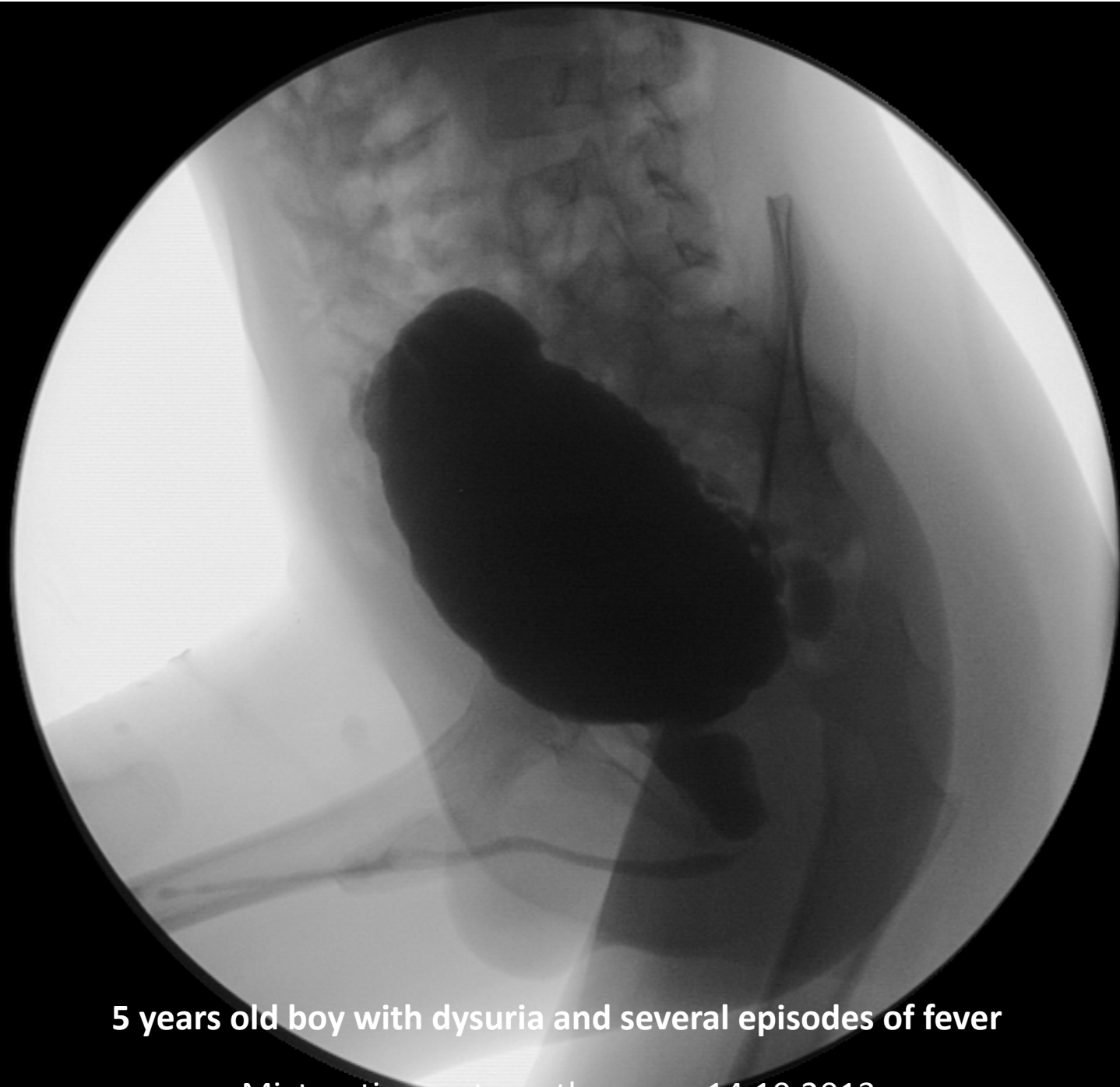


AXR 12.07.2014

Case 2

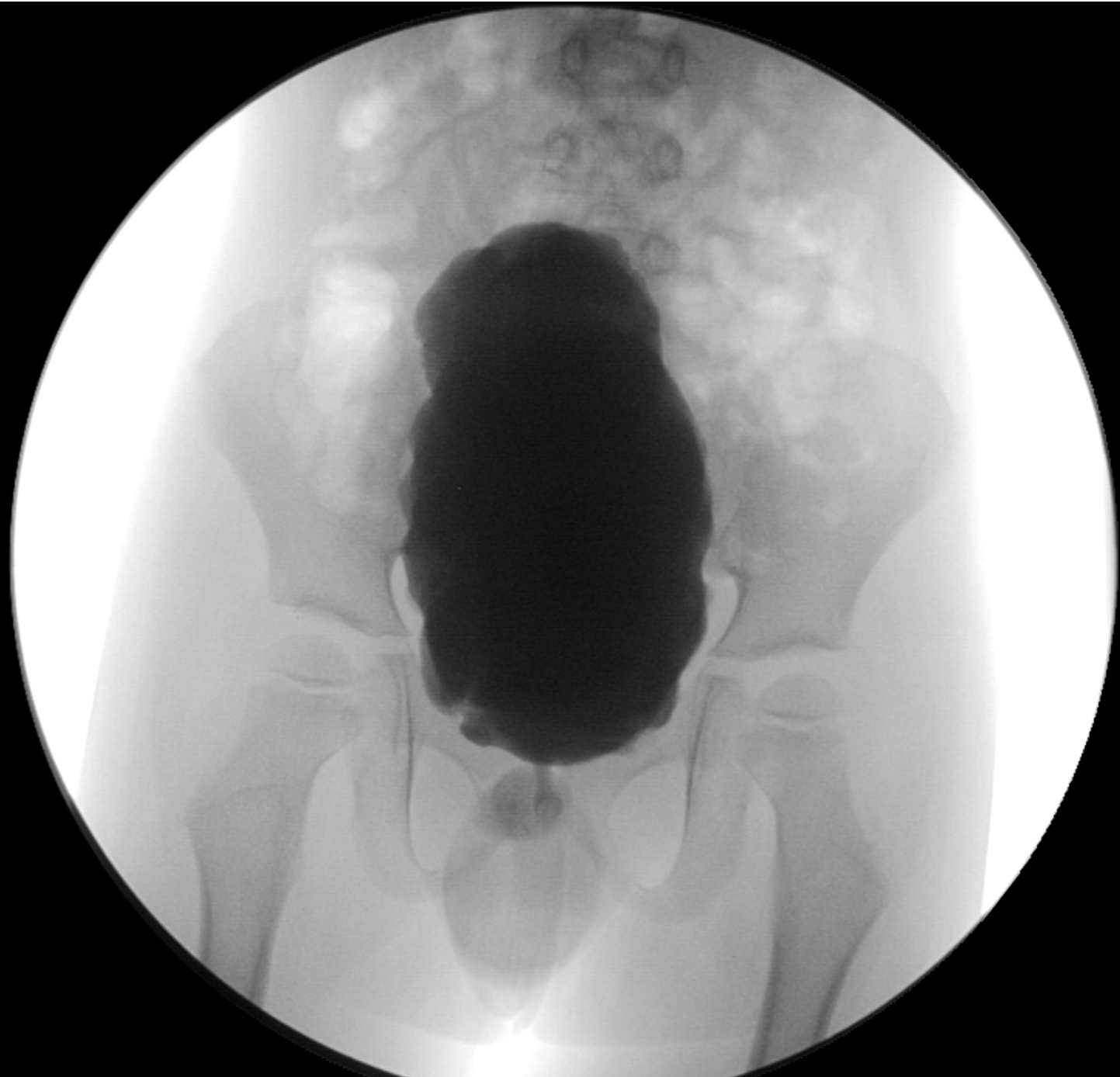


Medical Excellence



5 years old boy with dysuria and several episodes of fever

Micturating cystourethrogram 14.10.2013



Cystourethrogram 14.10.2013

Case 3

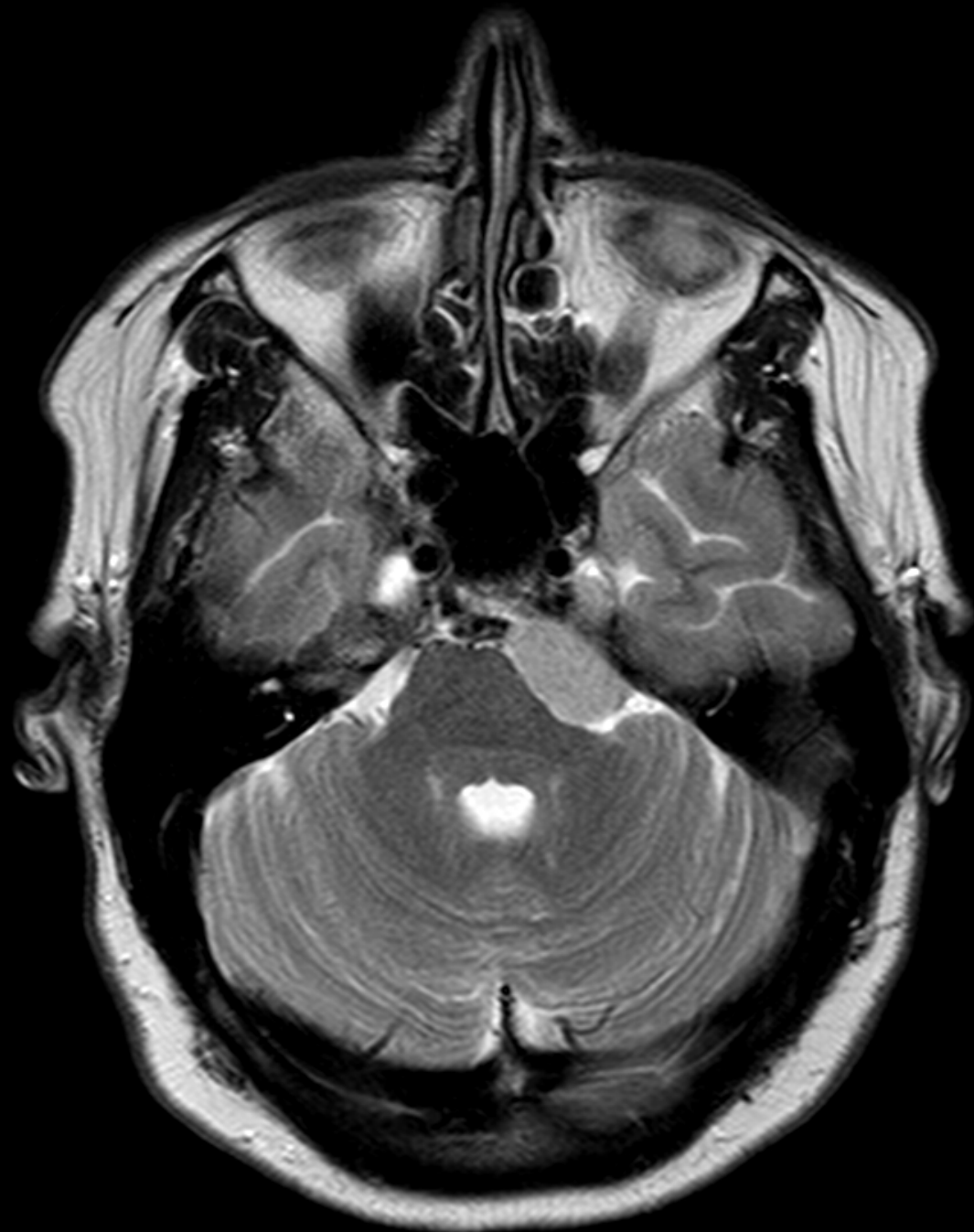

Medical Excellence

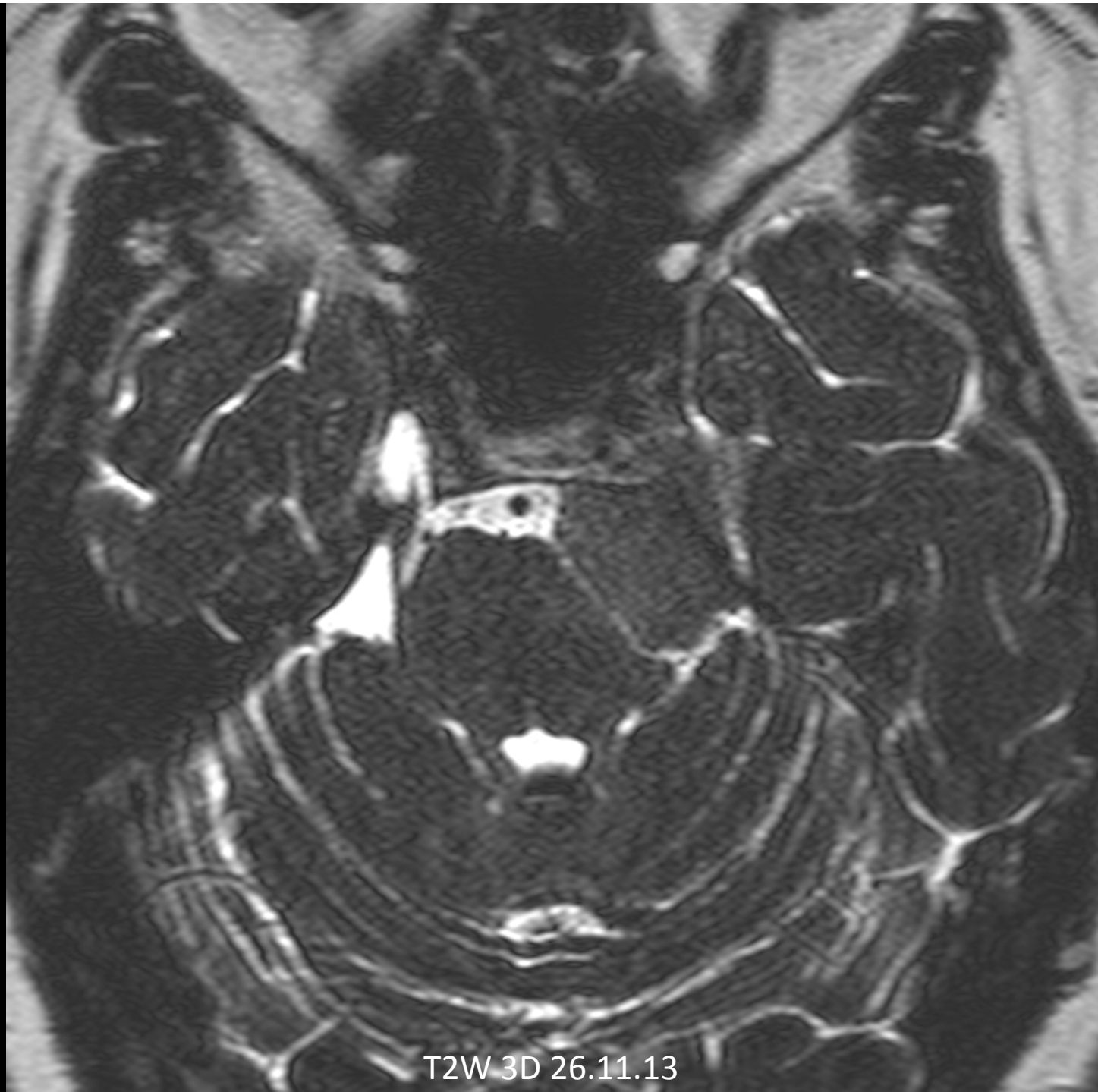Case 3

- 58 years old lady
- Feels like an electrical impulse on left side of her face for the last 15 days (lightning kind of pain) lasting 10s.
- 9-10 x a day

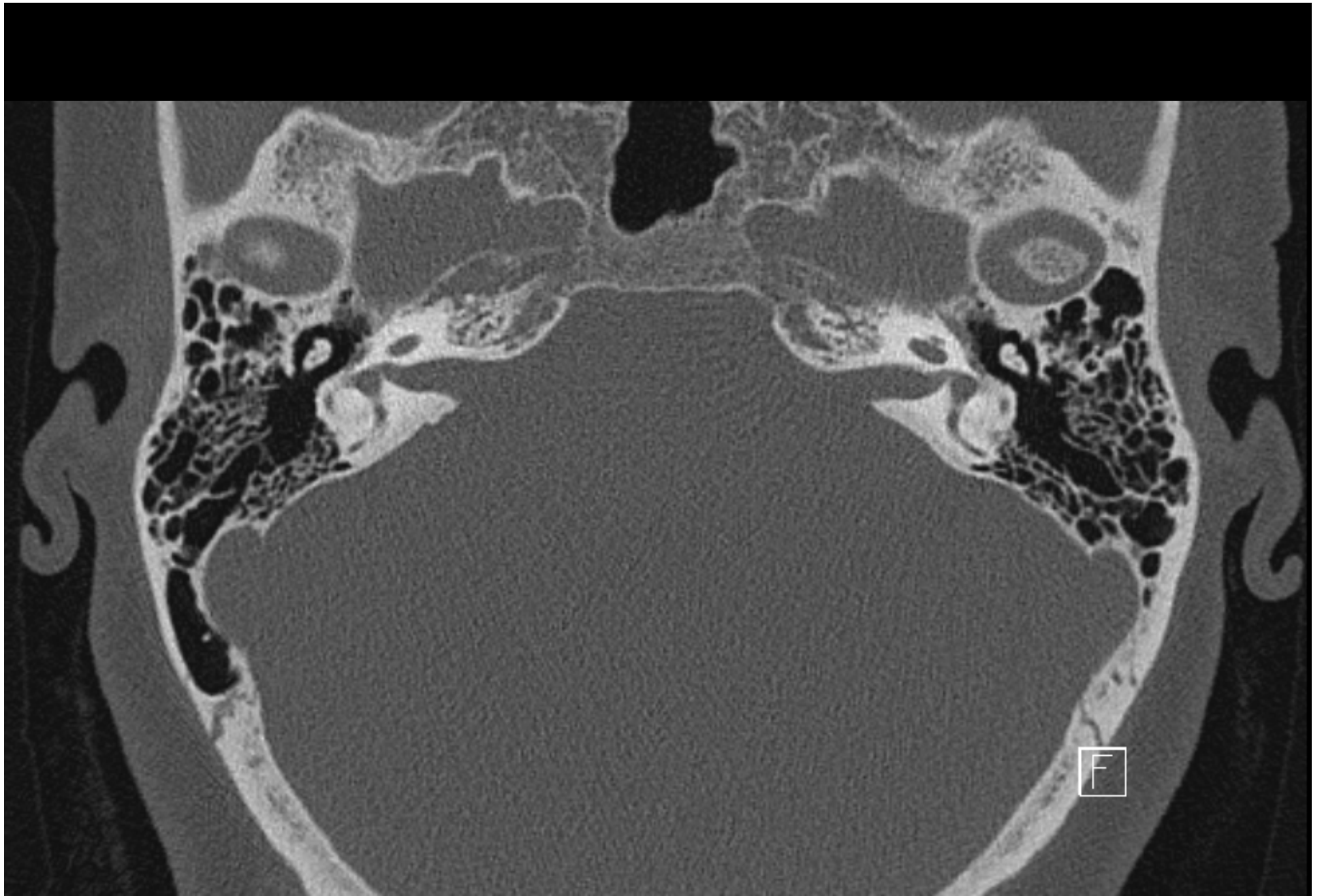



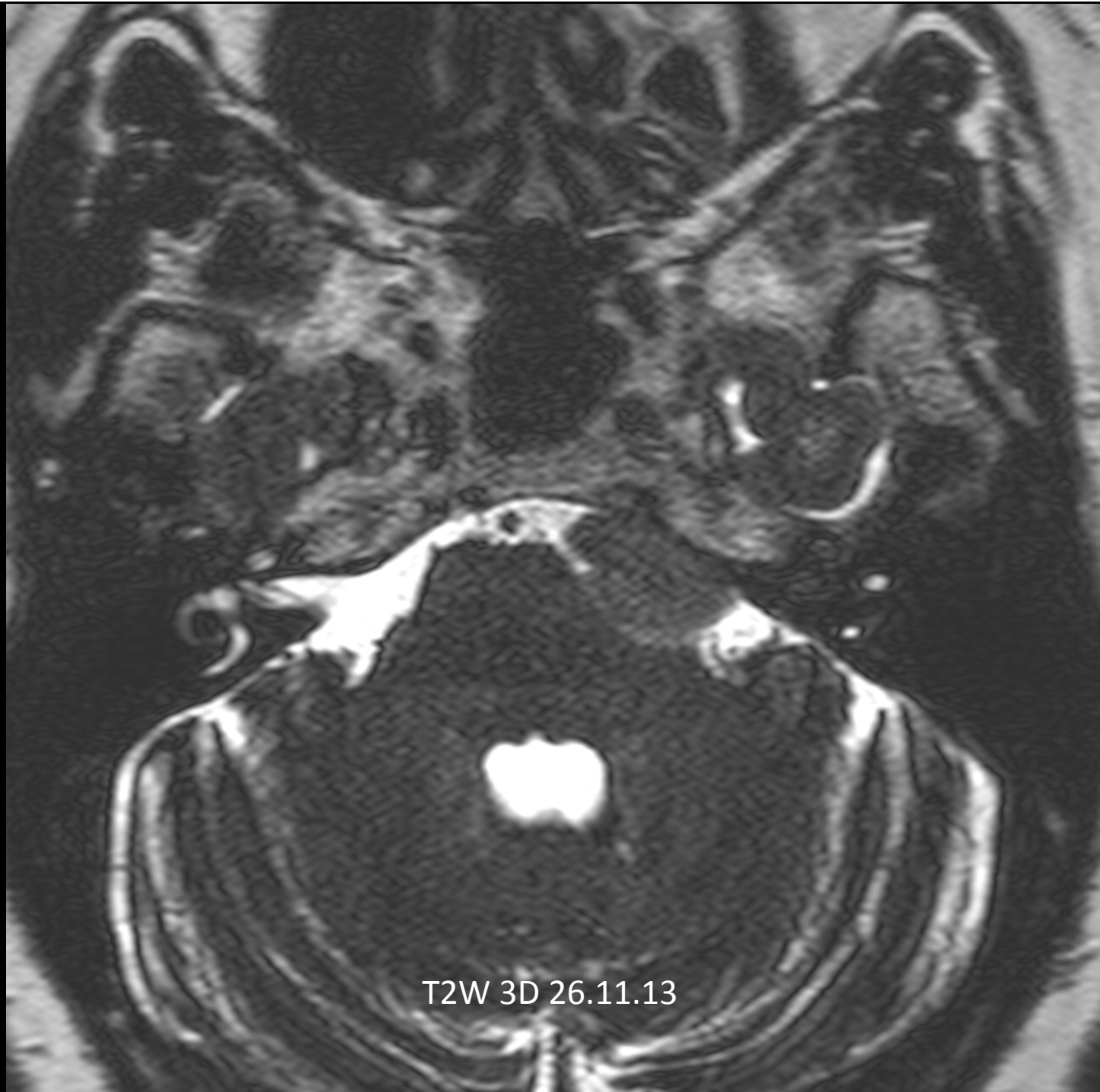
T2W 26.11.13



T2W 3D 26.11.13



- 28.11.2013 CT



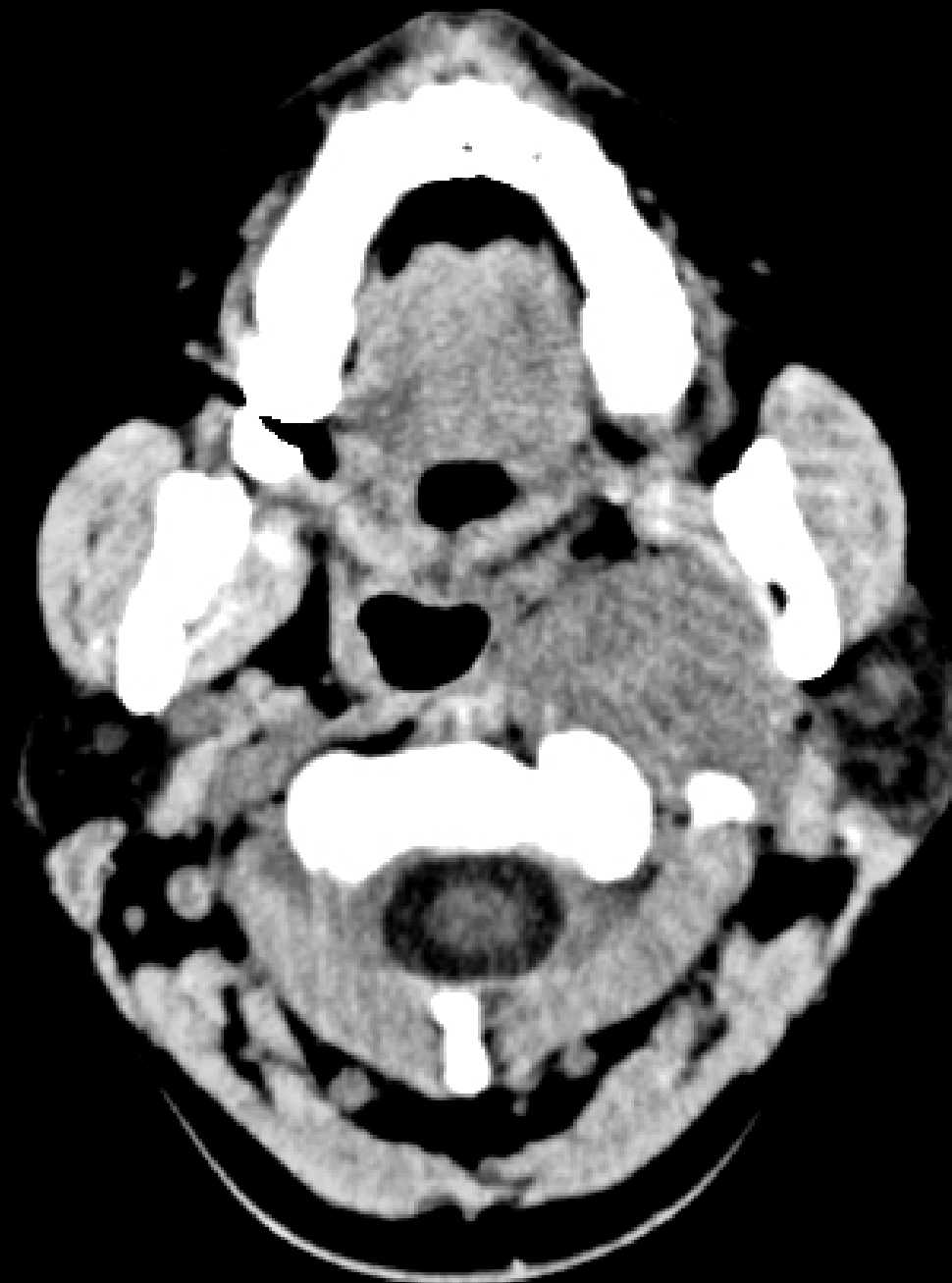T2W 3D 26.11.13

Case 4

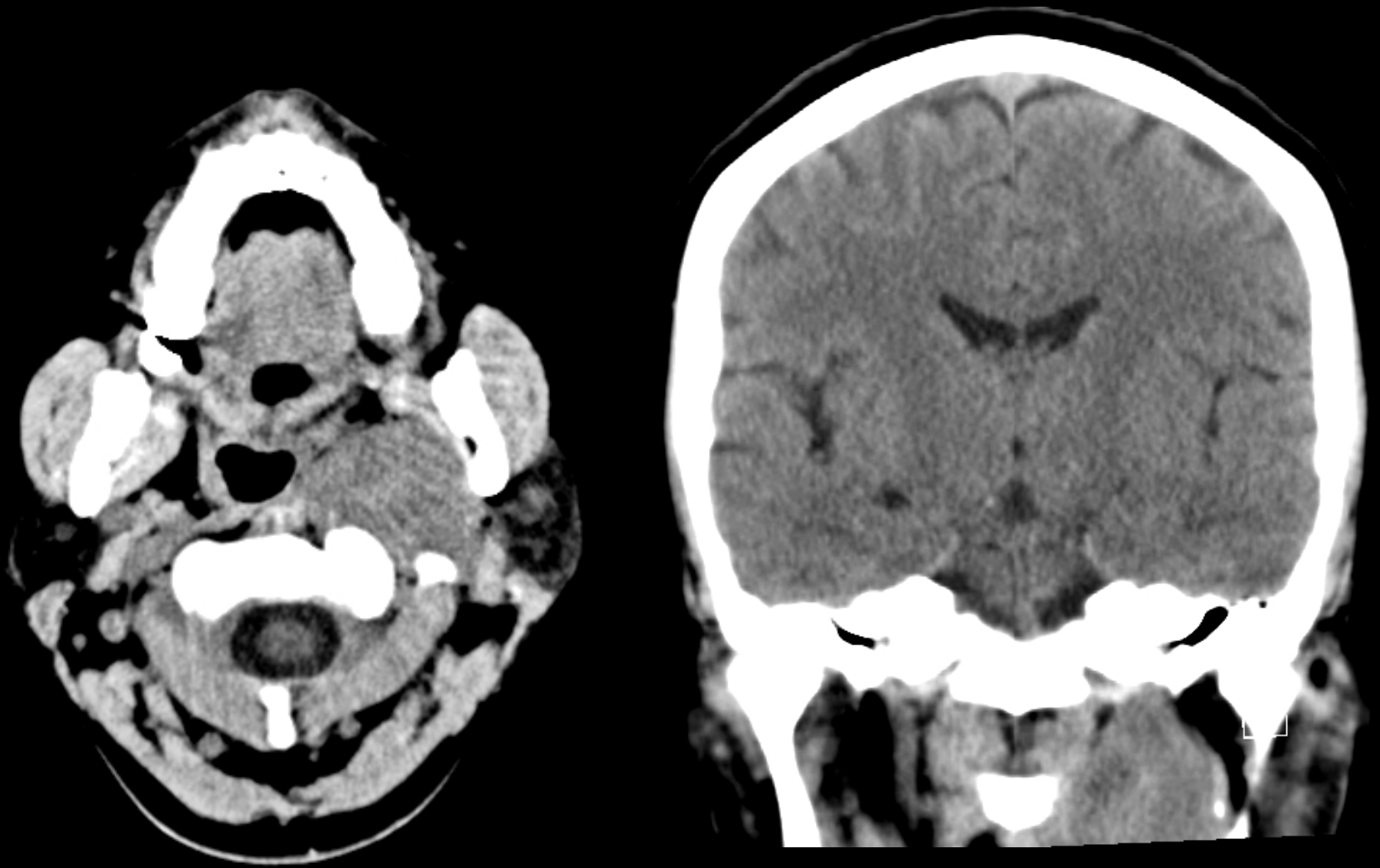


Medical Excellence

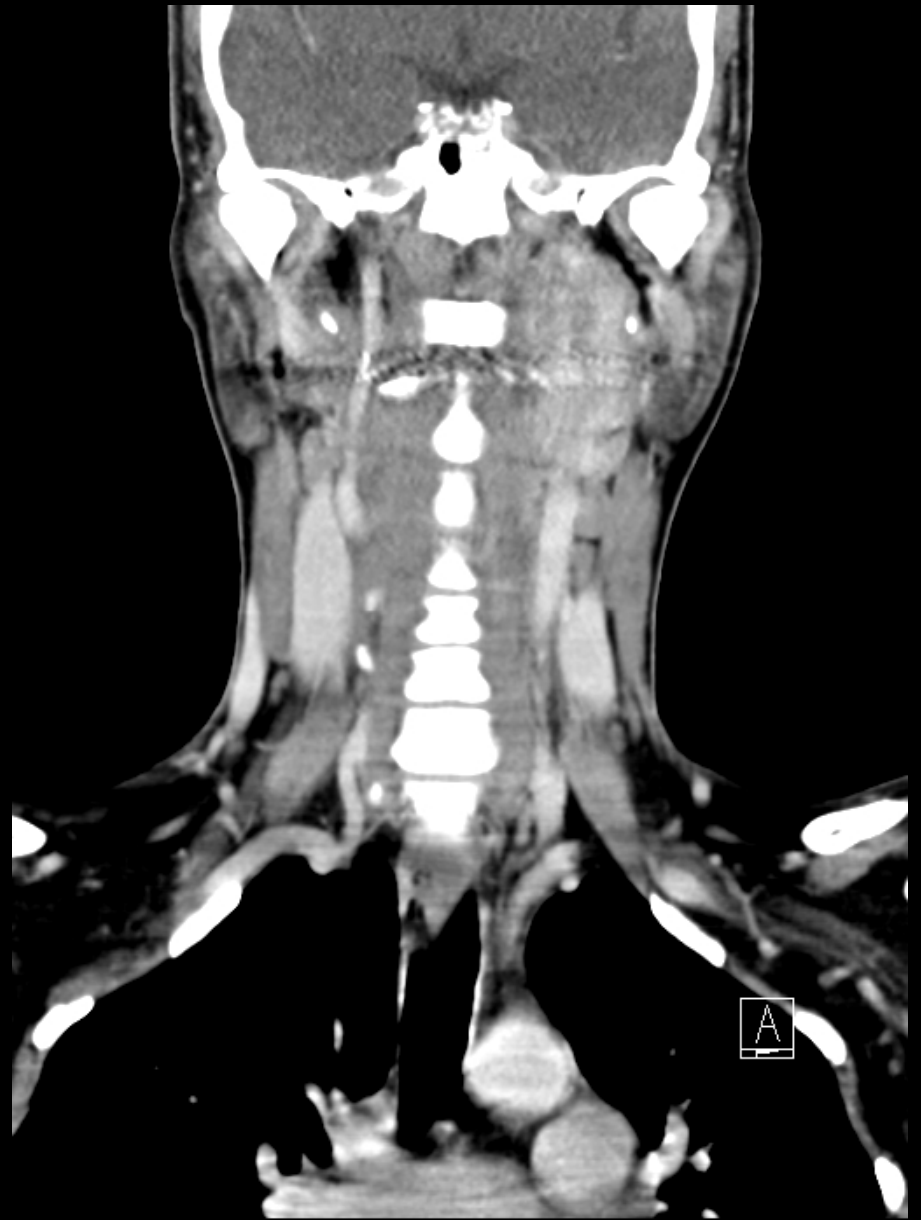
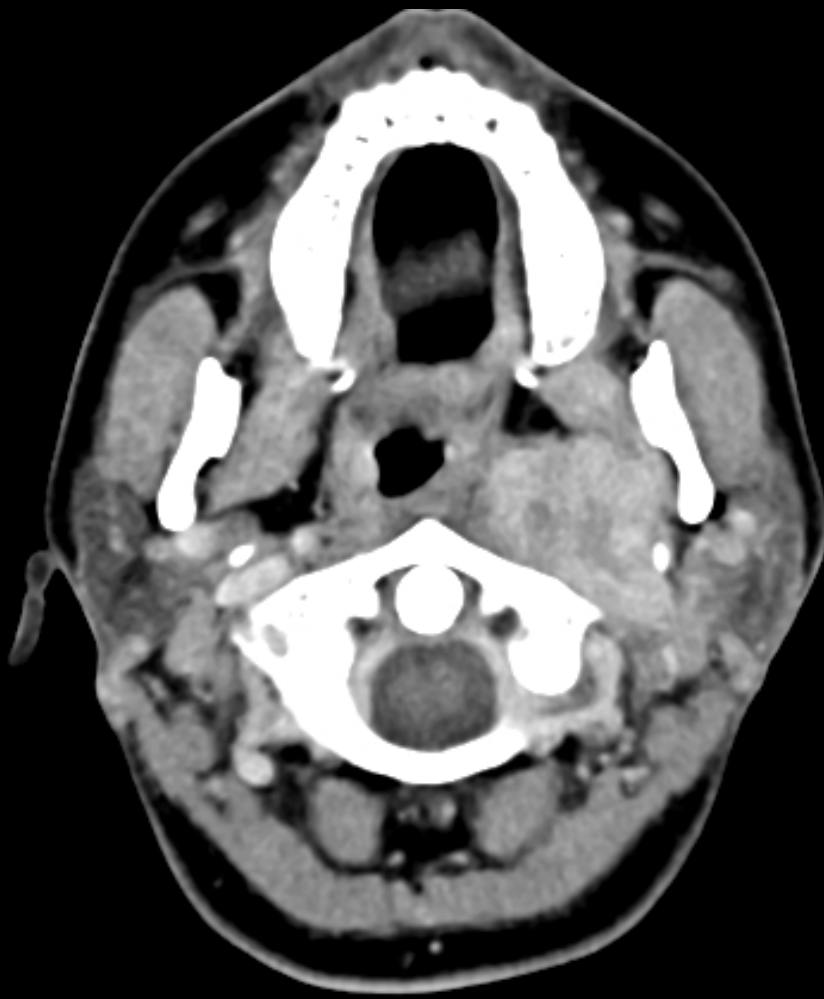49 years old lady
persisting cough
for 4 years, having
headache and light
headedness for
few weeks



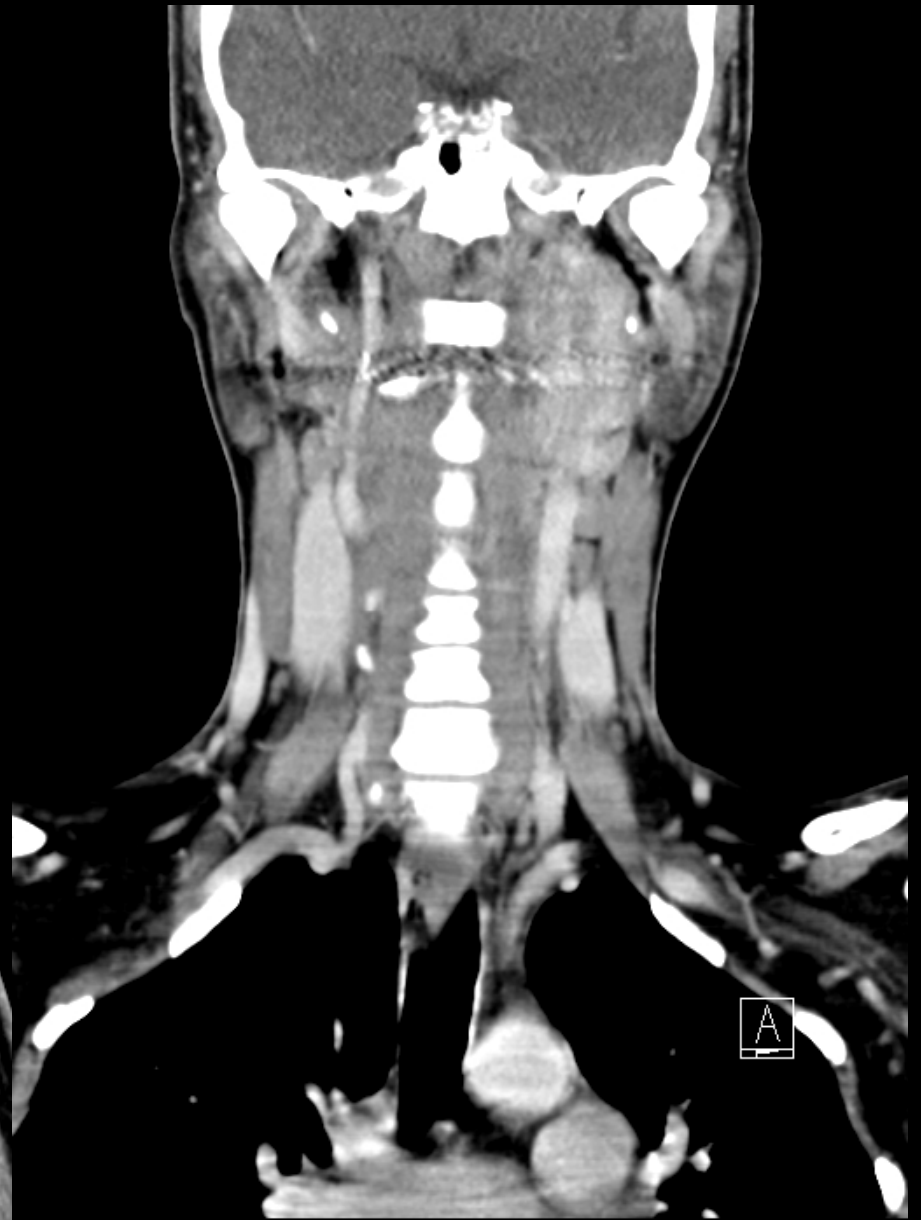
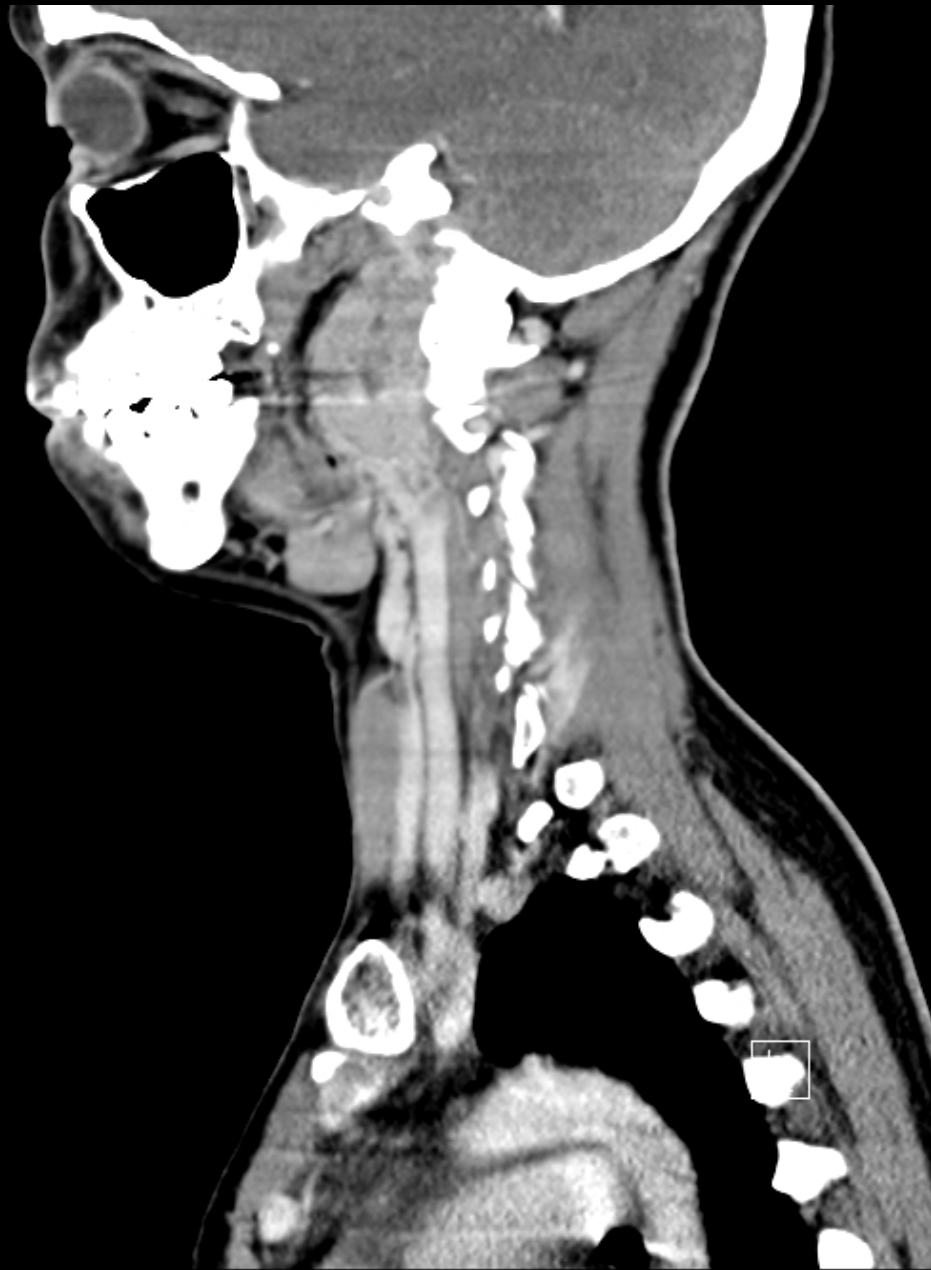PLAIN Brain CT 19.04.2013



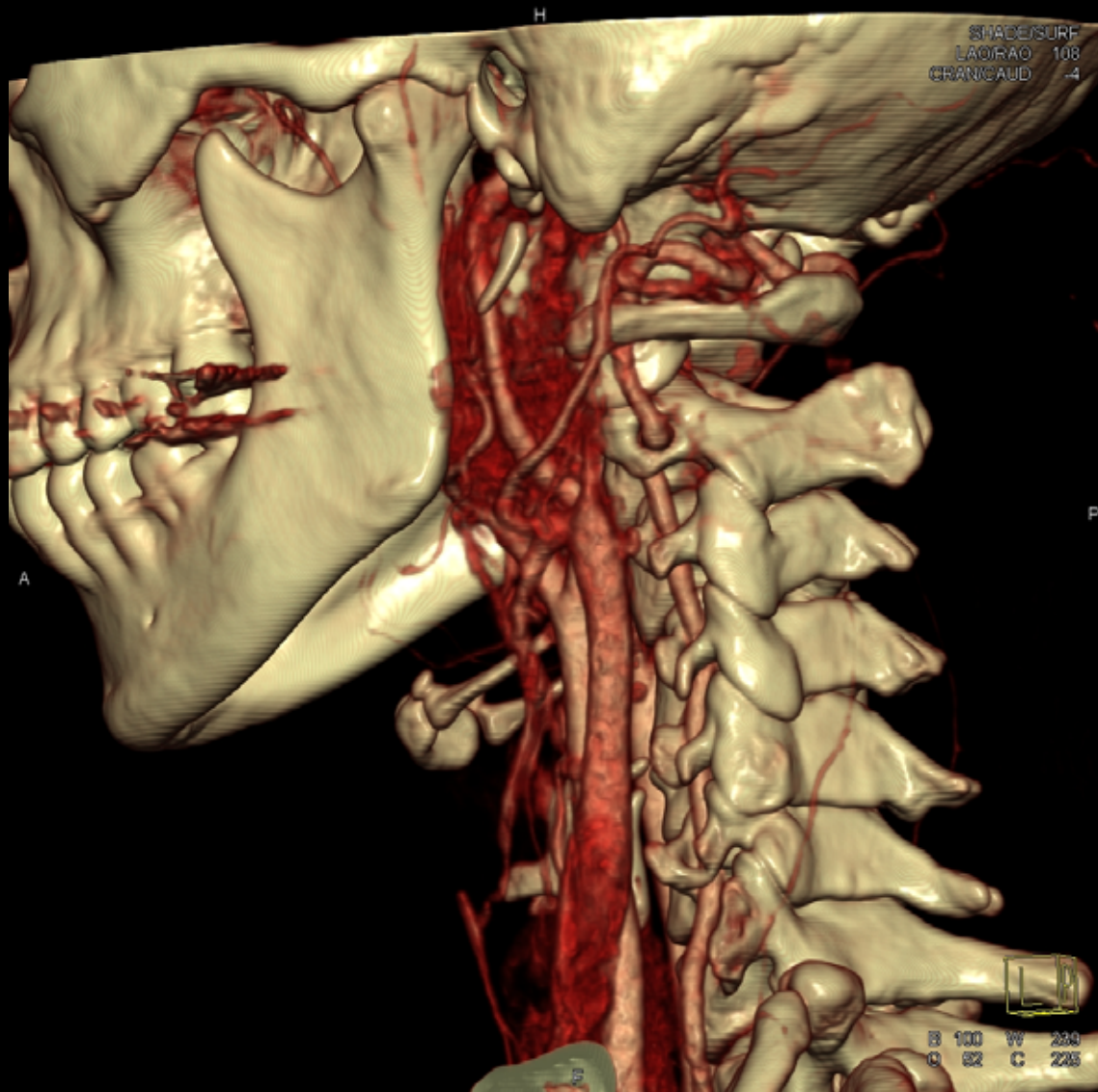PLAIN Brain CT 19.04.2013



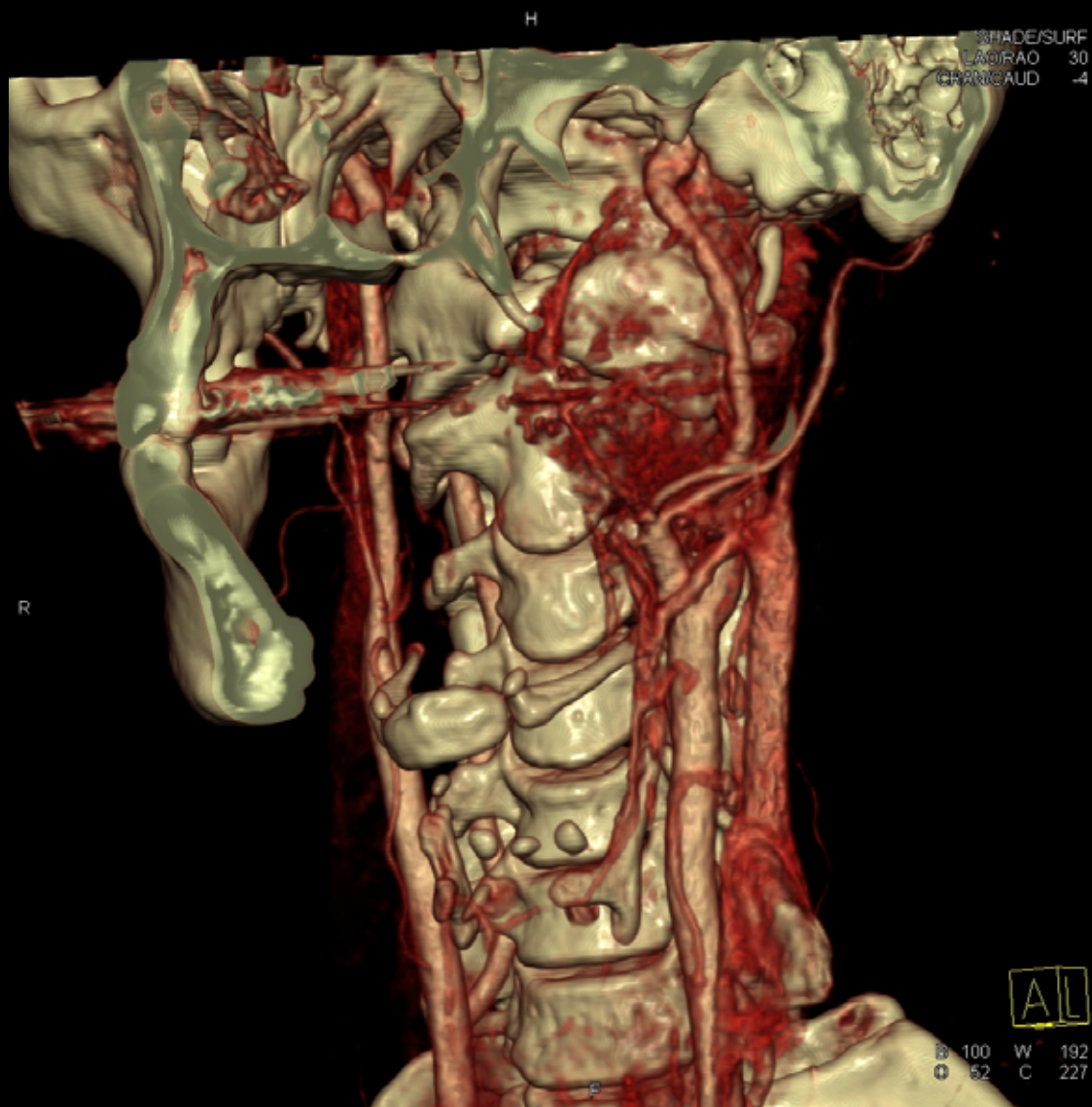
CECT Neck 26.04.2013



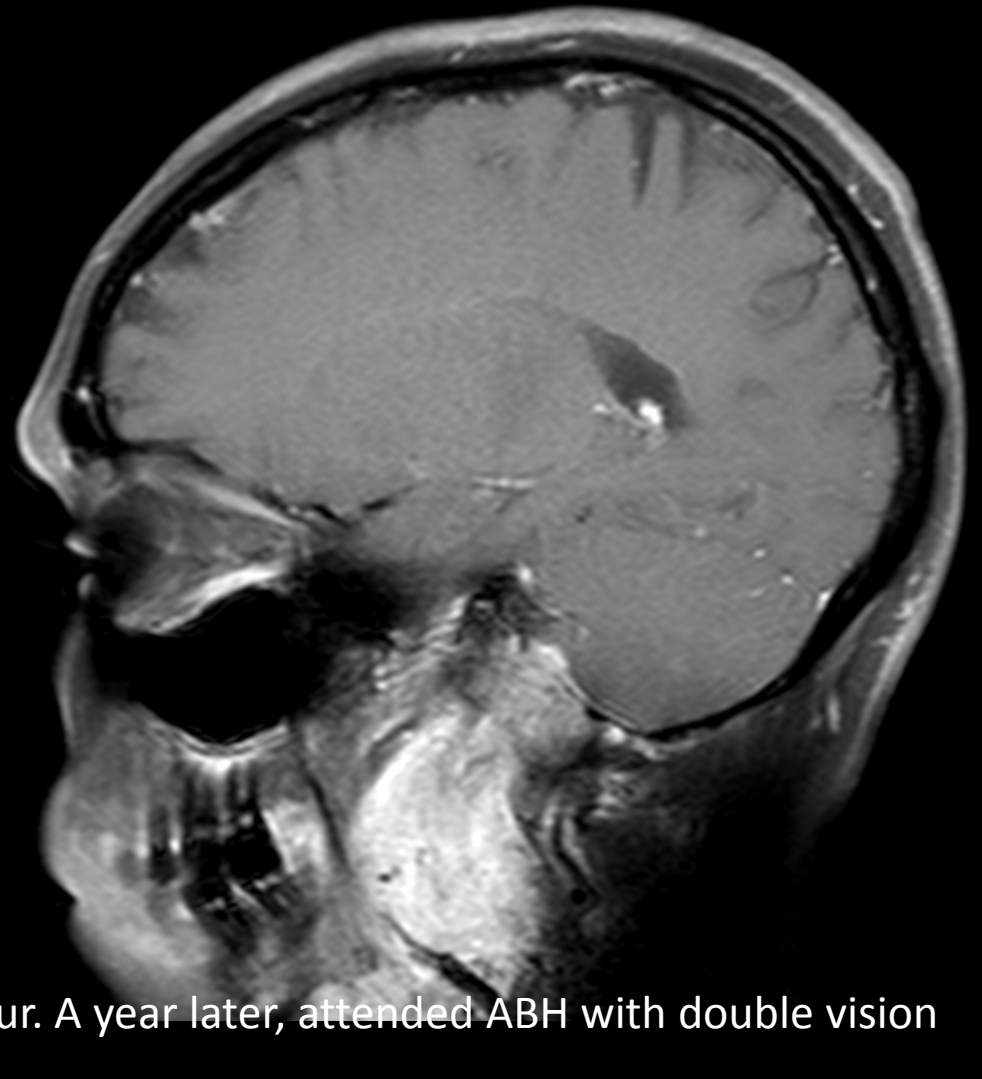
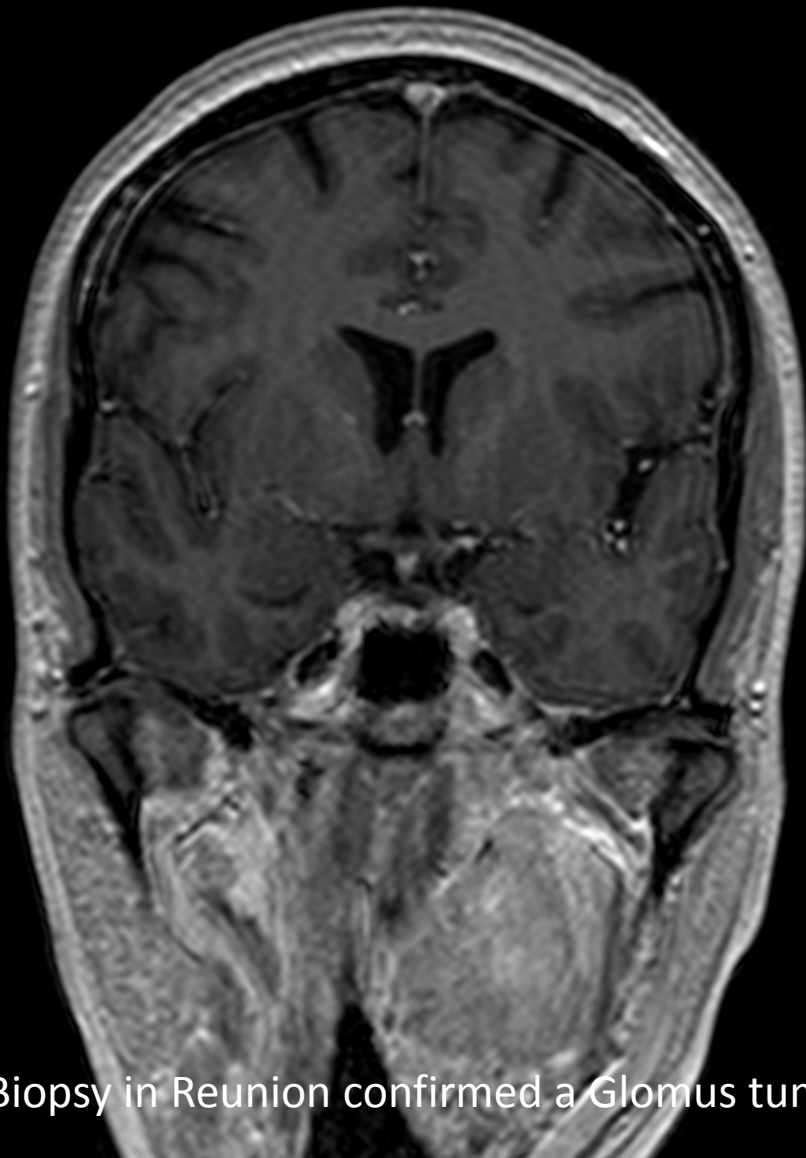
CECT 26.04.2013



VRT 26.04.2013

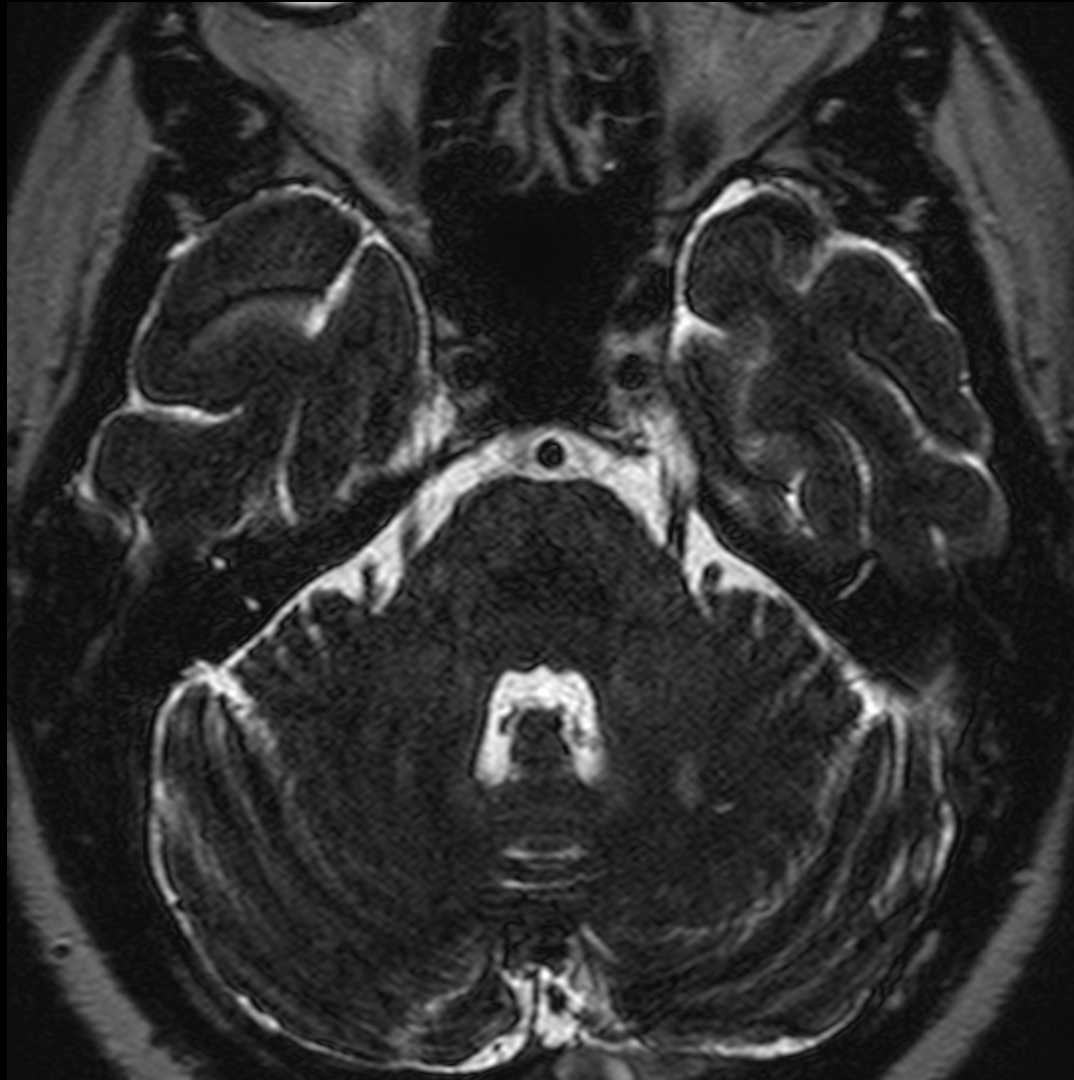

VRT 26.04.2013

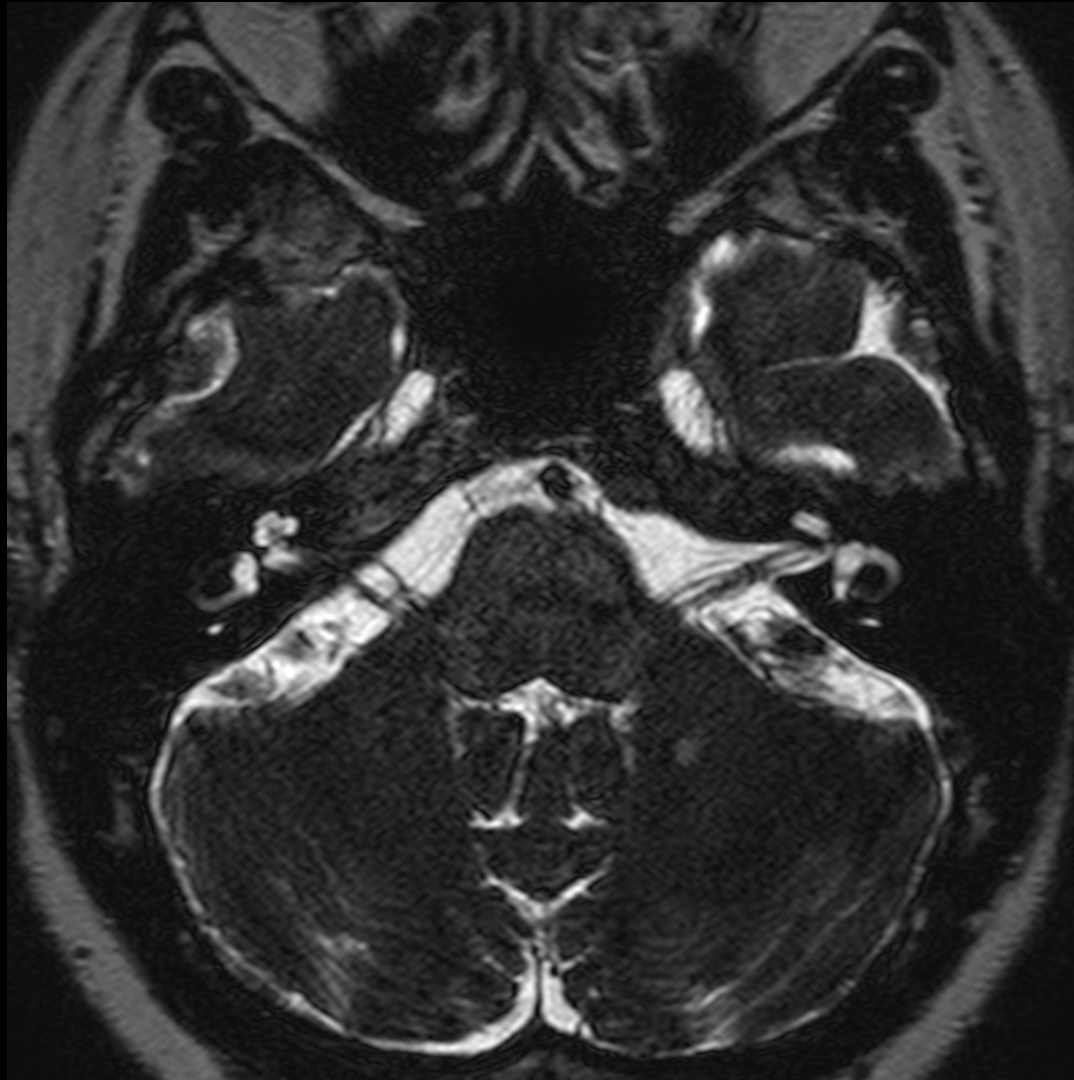

Biopsy in Reunion confirmed a Glomus tumour. A year later, attended ABH with double vision

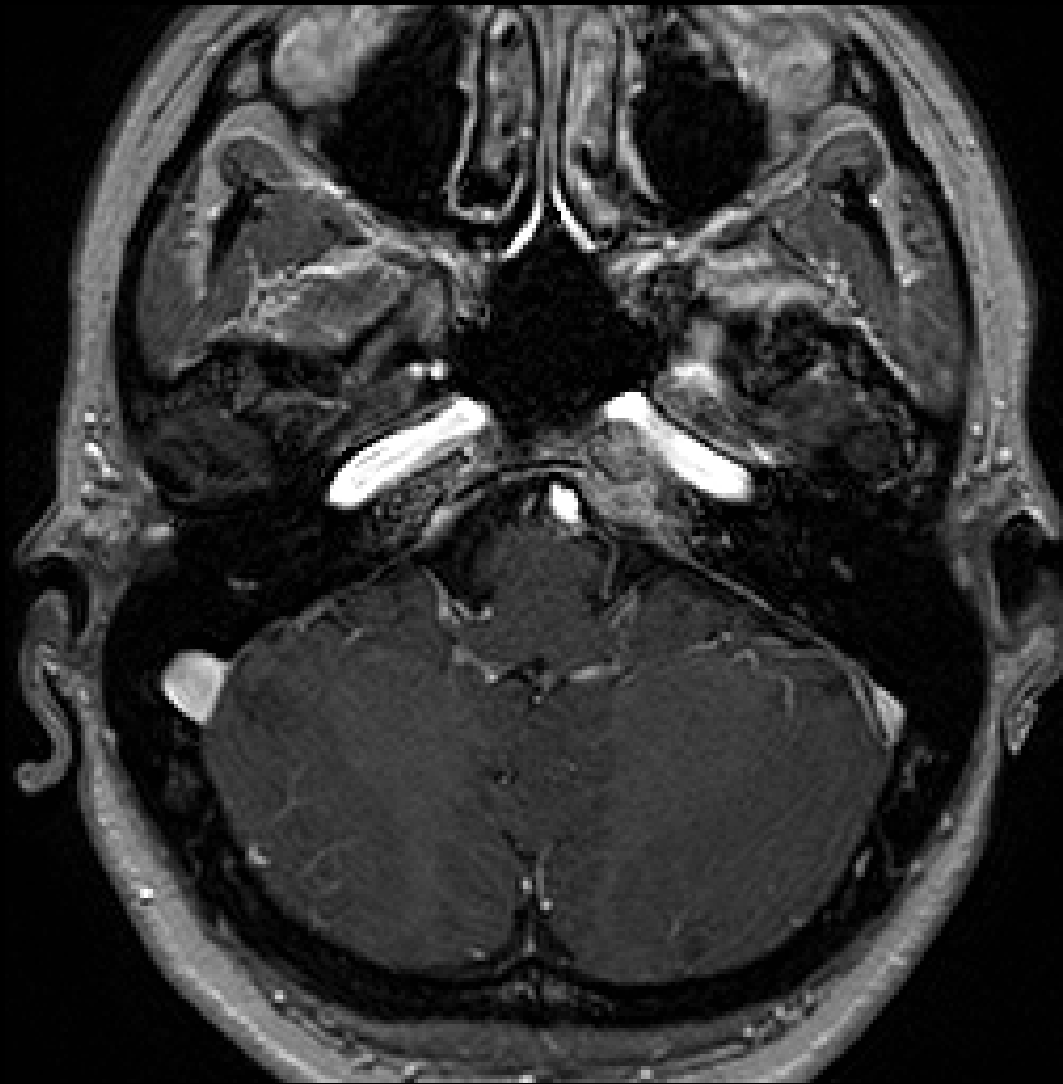
T1W Gd 28.06.2014



T2W 3D TSE AXIAL 28.06.2014



T2W 3D TSE AXIAL 28.06.2014



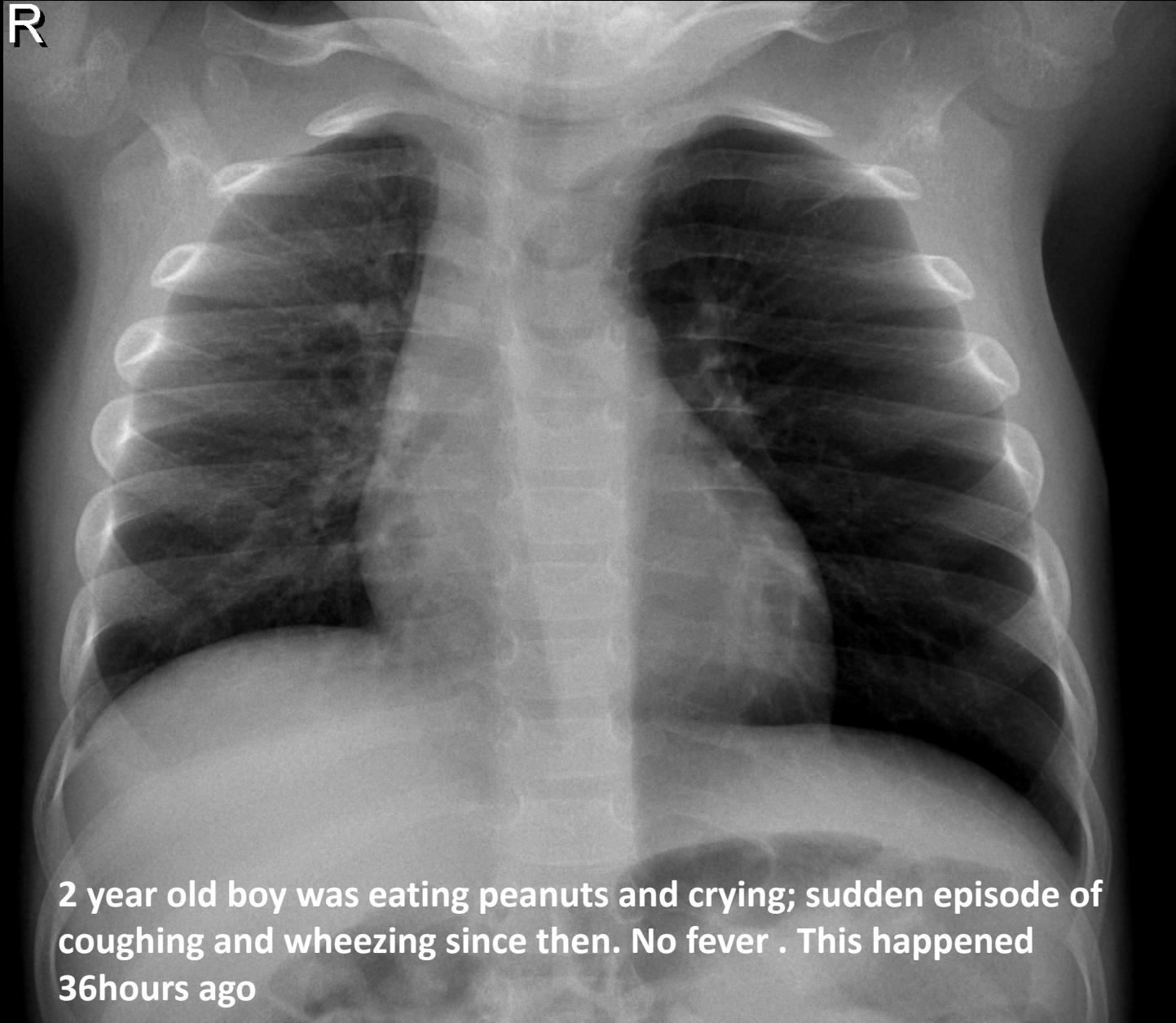
T1W 3D Gd AXIAL3 28.06.2014

Case 5



Medical Excellence

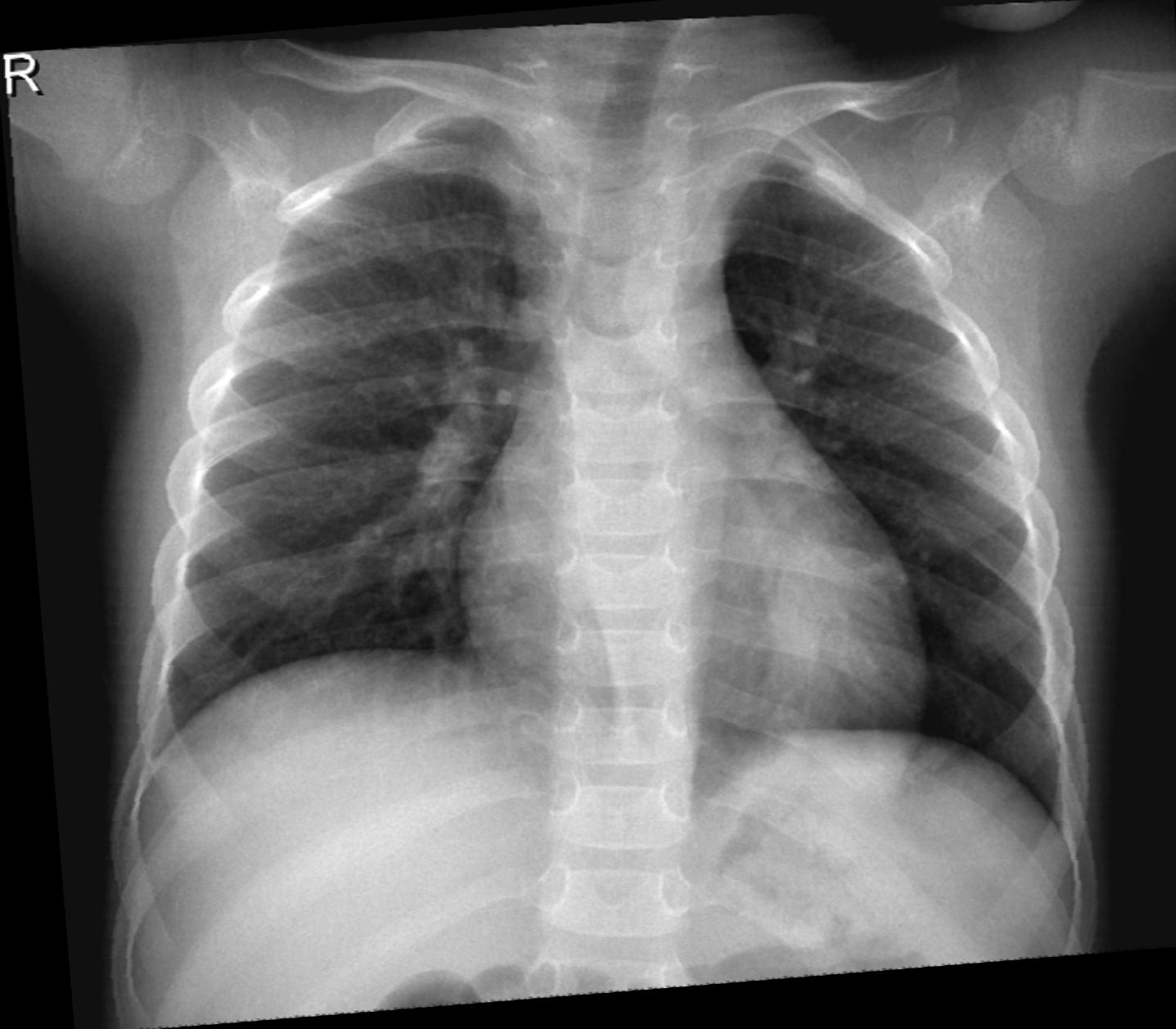R



2 year old boy was eating peanuts and crying; sudden episode of coughing and wheezing since then. No fever . This happened 36hours ago

CXR 23.06.14

R



CXR 25.06.14

Case 6

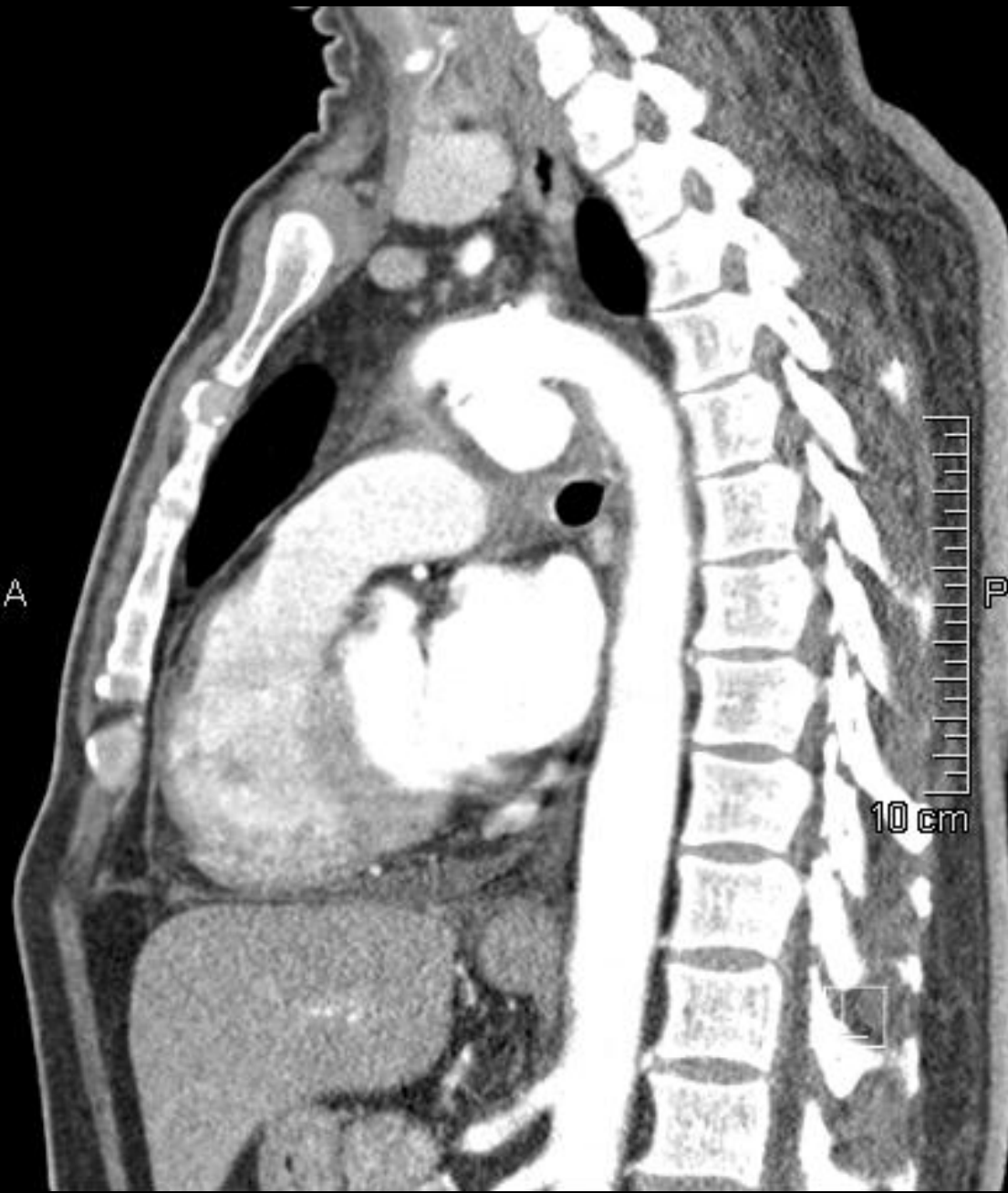

Medical Excellence

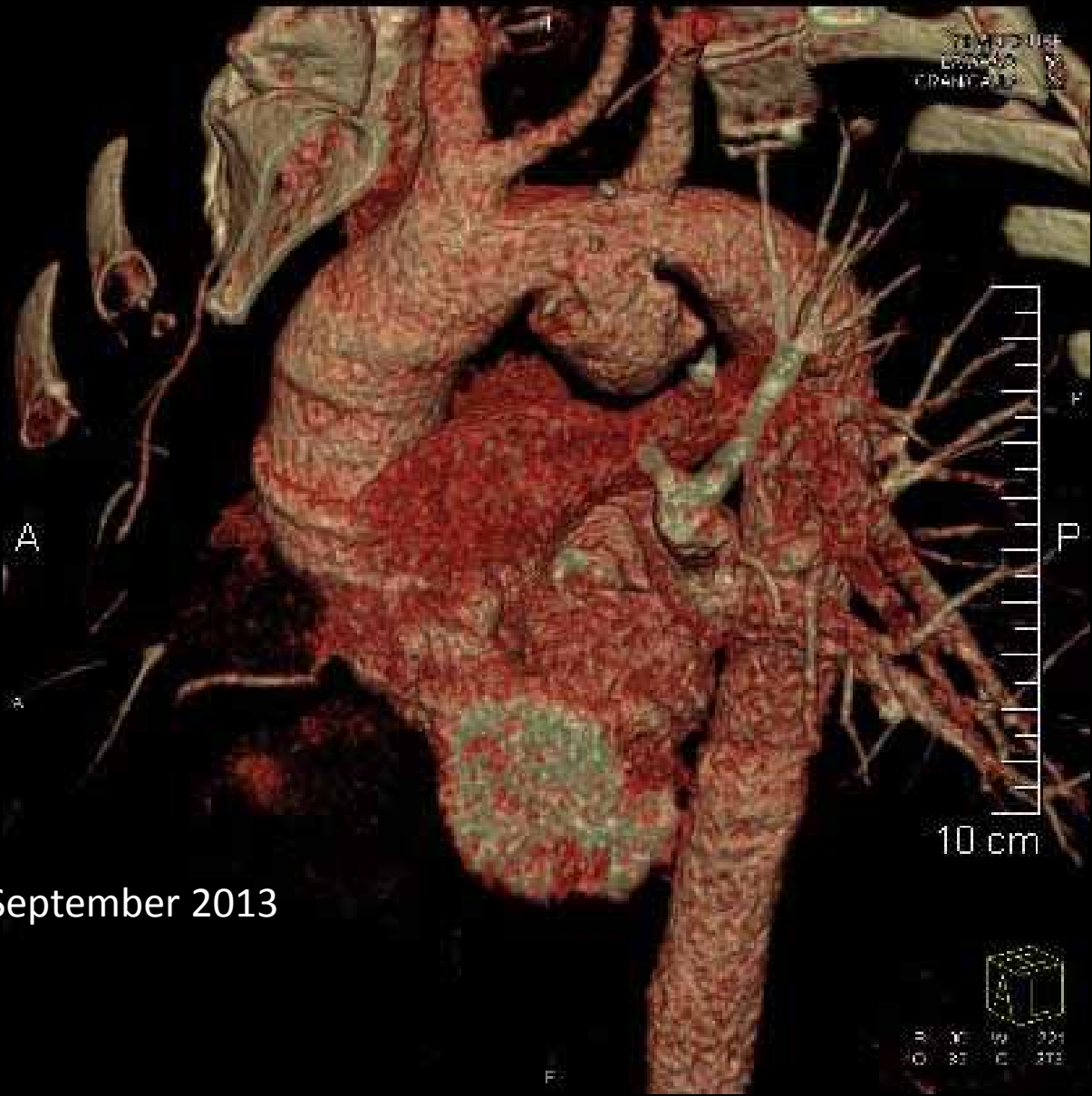Case 6

- 50 years old male presenting with hoarseness of voice
- What imaging would you recommend?



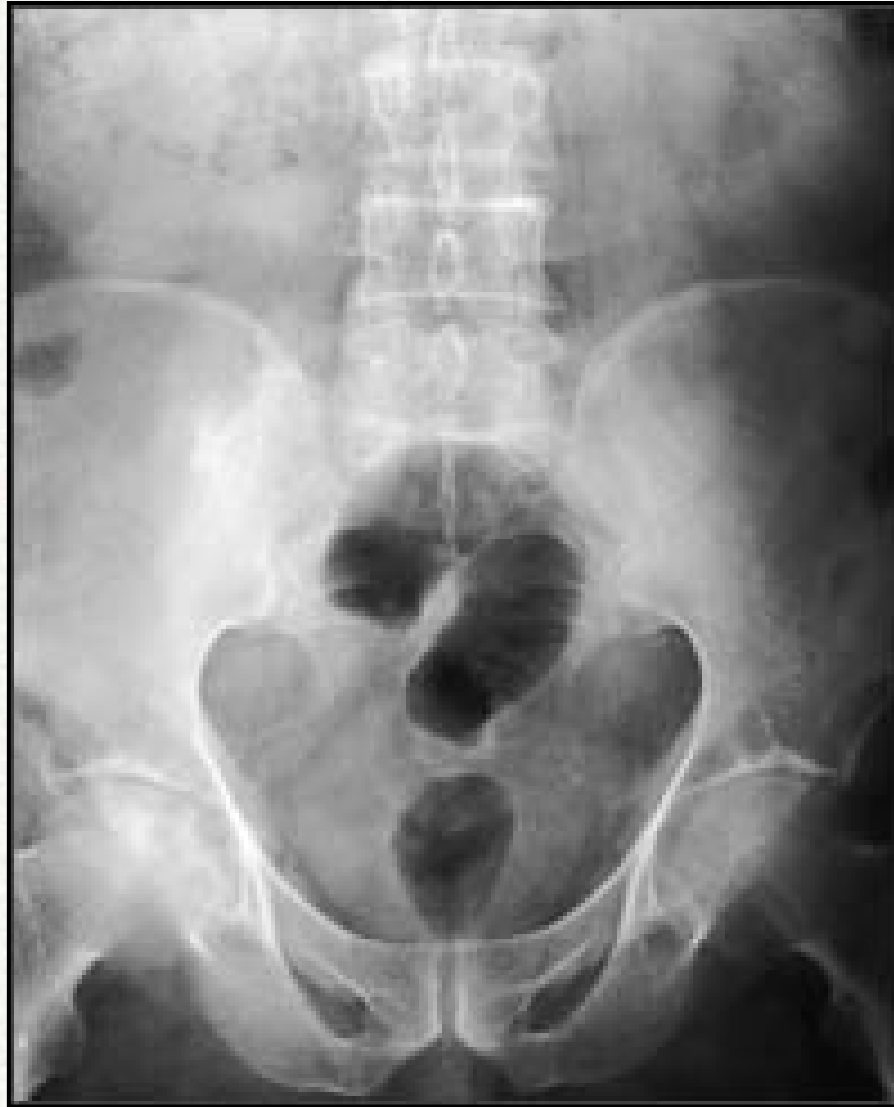

24.12.2013



CT normal in September 2013

24.12.2013



Medical Excellence

Concluding with Radiological Images THANK YOU

Date : 25.07.2014



Medical Excellence